



Breast Brachytherapy and a Case Report

İlknur ALSAN ÇETİN,¹ Seden KÜÇÜCÜK,² Işık ASLAY³

¹Department of Radiation Oncology, Marmara University, İstanbul-Turkey

²Department of Radiation Oncology, İstanbul University, İstanbul-Turkey

³Department of Radiation Oncology, Acibadem Hospital, İstanbul-Turkey

SUMMARY

For women who had breast-conserving surgery (BCS), brachytherapy can be used along with external beam radiation as a way to add an extra boost of radiation to the tumor site. It may also be used as a form of accelerated partial breast irradiation. Tumor size, location and other factors may affect brachytherapy decision. The patient was 47 years old and applied to İstanbul University Oncology Institute Radiation Oncology Department. A mass in the upper outer quadrant was detected. Invasive ductal cancer was diagnosed with biopsy. MKC and sentinel lymph node biopsy were performed in 2013. Histological and nuclear grade II, ER (+++), PG (+++), cerbB2 (-), lymphovascular invasion (-), pT1N0 was revealed. In 2013, 50 Gy/25 frx ERT was applied to the left breast tangent. After 16 days, HDR was performed twice daily (BID) (4x3Gy), 14-channel ISI breast implants. The reference dose is defined as 3 Gy GTV.

Keywords: Brachytherapy; breast cancer.

Copyright © 2019, Turkish Society for Radiation Oncology

Introduction

Breast-conserving surgery and radiotherapy are the standard treatment methods for early-stage breast cancer. Tumor bed recurrence rate after BCS is 60%–85%. Local control increases with a boost of 45–50 Gy and 10–16 Gy.[1,2] Recurrence in breast cancer is often around the tumor. The idea that irradiation of the primary tumor bed instead of the whole breast tissue is sufficient for local control has improved the approach of partial breast radiotherapy.[3,4] Briefly, it is the application of brachytherapy (BRT) within a margin of 1–2 cm to the primary tumor bed instead of the whole breast tissue. The treatment is completed in as short as 2 weeks with high-dose administration. It also improves patient compliance. This application can be applied in BRT and intraoperatively, and both have advantages and disadvantages. However, most commonly BRT involves interstitial (ISI) and intracavitary practice. Th-

ese applications can be in the forms of LDR, HDR, or PDR. Catheters can be intraoperatively or postoperatively placed.

Case Report

The case patient was aged 47 years who presented to İstanbul University Oncology Institute Radiation Oncology Department. A mass was detected in the upper outer quadrant, and invasive ductal cancer was diagnosed by biopsy. MKC and sentinel lymph node biopsy were performed in 2013. The following findings were revealed: histological and nuclear grade II, ER (+++), PG (+++), cerbB2 (-), lymphovascular invasion (-), and pT1N0. In 2013, 50 Gy/25 frx ERT was applied to the left breast tangent. After 16 days, HDR was performed twice daily (4x3 Gy), and 14-channel ISI breast implants were used. The reference dose was 3 Gy GTV (Figs. 1–2).

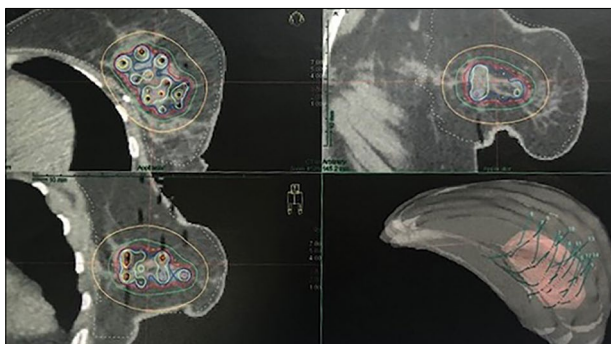


Fig. 1. Dose distribution after breast implantation.

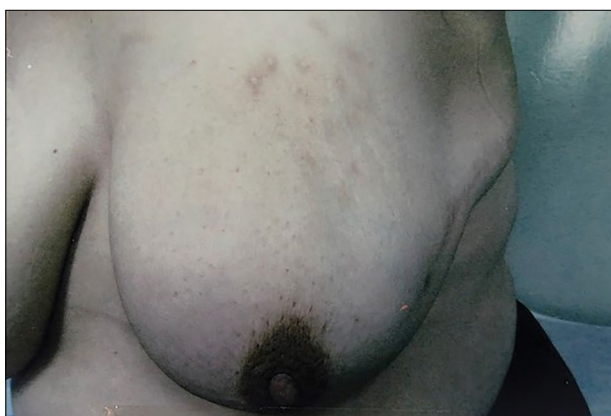


Fig. 2. Cosmetic results after 1 year.

Discussion

Because of its high-dose distribution, ISI implant is preferred for patients with large mammalian, deep-seated tumors and those with surgical margins.[2] It is recommended to apply 12–20 Gy of 4–6 frx in HDR and be placed in an ISI implant under local anesthesia. In a study by Gabani et al., 175 patients who underwent accelerated partial breast irradiation (APBI) with accelerated ISI-HDR had high survival, local control, and good cosmetic results.[5] In previous randomized studies, no difference was found between ISI-BRT and electron treatments between survival and local control.[6–10]

In intracavitary BRT applications, silicone balloons of 4–6-cm diameter and 1–8 channel catheters can be used. A balloon is inflated with saline after its placement in the lumpectomy cavity. The prescribed dose is planned 1 cm beyond the surface of the balloon.[11] The most common dose for HDR is 3.4Gy for each frx, in total 34 Gy (5 days, twice a day). CT, MR, USG, and clips for CTV definition can be used.[12,13] In breast BRT, treatment of small implant volumes may result in high recurrence.[14] Therefore, a margin of 2 cm around the lumpectomy cavity is recommended as it

increases local control. Excellent cosmetic results and local control were obtained with balloon-based BRT in APBI studies.[11,15] Additionally, Vicini et al. found that a large tumor (>2 cm) and smaller skin sparing (<7 mm) were the crucial independent predictors of cosmesis.[13]

Conclusion

Based on a large number of studies, BRT is considered a safe and effective method for appropriate patients. Since it is an invasive and complicated technique, it should be applied in experienced centers.

Peer-review: Externally peer-reviewed.

Conflict of Interest: The authors have no of interest.

Financial Support: None declared.

Authorship contributions: Concept – İ.A.Ç., S.K., İ.A.; Design – İ.A.Ç., S.K., İ.A.; Supervision – İ.A.Ç., S.K., İ.A.; Materials – İ.A.Ç., S.K., İ.A.; Data collection &/or processing – İ.A.Ç.; Analysis and/or interpretation – İ.A.Ç.; Literature search – İ.A.Ç.; Writing – İ.A.Ç., S.K., İ.A.; Critical review – İ.A.Ç.

References

1. Fisher B, Anderson S, Byrant J, Margolese RG, Deutsch M, Fisher ER, et al. Twenty-year follow-up of a randomized trial comparing total mastectomy, lumpectomy, and lumpectomy plus irradiation for the treatment of invasive breast cancer. *N Eng J Med* 2002;347(16):1233–41.
2. Veronesi U, Cascinelli N, Mariani L, Greco M, Saccozzi R, Luini A, et al. Twenty-year follow-up of a randomized study comparing breast-conserving surgery with radical mastectomy for early breast cancer. *N Engl J Med* 2002;347(16):1227–32.
3. Marta GN, Macedo CR, Carvalho HdeA, Hanna SA, da Silva JL, Riera R. Accelerated partial irradiation for breast cancer: systematic review and metaanalysis of 8653 women in eight randomized trials. *Radiother Oncol* 2015;114(1):42–9.
4. Hepel JT, Wazer DE. A comparison of brachytherapy techniques for partial breast irradiation. *Brachytherapy* 2012;11(3):163–75.
5. Gabani P, Cry AE, Zoberi JE, Ochoa LL, Matesa MA, Thomas MA, et al. Long-term outcomes of APBI via multicatheter interstitial HDR brachytherapy: Results of a prospective single- institutional registry. *Brachytherapy* 2018;17(1):171–80.
6. Polgar C, Fodor J, Major T, Sulyok Z, Kasler M. Breast-conserving therapy with partial or whole breast irradiation: ten years results of the Budapest randomized trial. *Radiother Oncol* 2013;108(2):197–202.

7. Strnad V, Ott OJ, Hildebrandt G, Kauer-Dorner D, Knauerhase H, Major T, et al; Groupe Européen de Curiethérapie of European Society for Radiotherapy and Oncology (GEC-ESTRO). 5-year results of accelerated partial breast irradiation using sole interstitial multicatheter brachytherapy versus whole-breast irradiation with boost after breast-conserving surgery for low-risk invasive and in-situ carcinoma of the female breast: a randomised, phase 3, non-inferiority trial. *Lancet* 2016;387(10015):229–38.
8. Polgár C, Ott OJ, Hildebrandt G, Kauer-Dorner D, Knauerhase H, Major T, et al; Groupe Européen de Curiethérapie of European Society for Radiotherapy and Oncology (GEC-ESTRO). Late side-effects and cosmetic results of accelerated partial breast irradiation with interstitial brachytherapy versus whole-breast irradiation after breast-conserving surgery for low-risk invasive and in-situ carcinoma of the female breast: 5-year results of a randomised, controlled, phase 3 trial. *Lancet Oncol* 2017;18(2):259–68.
9. Shah C, Vicini F, Shaitelman SF, Hepel J, Keisch M, Arthur D, et al. The American Brachytherapy Society consensus statement for accelerated partial-breast irradiation. *Brachtherapy* 2018;17(1):154–70.
10. Rabinovitch R, Winter K, Kuske R, Bolton J, Arthur D, Scroggins T, et al. RTOG 95-17, a Phase II trial to evaluate brachytherapy as the sole method of radiation therapy for Stage I and II breast carcinoma -year-5 toxicity and cosmesis. *Brachtherapy* 2014;13(1):17–22.
11. Vicini FA, Keisch M, Shah C, Goyal S, Khan AJ, Beitsch PD, et al. Factors associated with optimal long-term cosmetic results in patients treated with accelerated partial breast irradiation using balloon-based brachytherapy. *Int J Radiat Oncol Biol Phys* 2012;83(2):512–8.
12. Sedlmayre F, Rahim HB, Kogelnik HD, Menzel C, Merz F, Deutschmann H, et al. Quality assurance in breast cancer brachytherapy: Geographic miss in the interstitial boost treatment of the tumor bed. *Int J Radiat Oncol Bio Phys* 1996;34(5):1133–9.
13. Vicini FA, Jaffray DA, Horwitz EM, Edmundson GK, DeBiose DA, Kini VR, et al. Implementation of 3D-virtual brachytherapy in the management of breast cancer: A description of a new method of interstitial brachytherapy. *Int J Radiat Oncol Biol Phys* 1998;40(3):629–35.
14. Fentiman IS, Poole C, Tong D, Winter PJ, Gregory WM, Mayles HM, et al. Inadequacy of iridium implant as sole radiation treatment for operable breast cancer. *Eur J cancer* 1996;32A(4):608–11.
15. Cuttino LW, Arthur DW, Vicini F, Todor D, Julian T, Mukhopadhyay N. Long-term results from the contour multilumen balloon breast brachytherapy catheter phase 4 registry trial. *Int J Radiat Oncol Biol Phys* 2014;90(5):1025–9.