



# A Historical, Histogenetic, and Proliferative Approach to Aneurysmal Bone Cyst

Nihan AKSAKALLI, Vakur OLGAC

<sup>1</sup>Department of Tumour Pathology, İstanbul University, Institute of Oncology, İstanbul-Turkey

## OBJECTIVE

The pathogenesis, cell origin, nomenclature, and clinical behavior of aneurysmal bone lesions have been discussed since the first appearance of an aneurysmal bone cyst (ABC). The aim of the present study was to investigate the origins of the different cells constituting aneurysmal bone lesions and to explain the different clinical behaviors of these lesions.

## METHODS

In the present investigation, the study group consisted of 30 cases of primary ABC, 24 cases of solid or aggressive aneurysmal bone cyst (SABC), and one case of aneurysmal bone cyst with nuclear pleomorphism (ABCNP) that are aneurysmal bone lesions (ABL) showing different biological behaviors. A cell origin study was performed with Factor VIII-related antigen (RAG), CD 34, and CD 68 antibodies. To show cell proliferations and evaluate the biological behavior of ABLs, AgNOR counts and immunohistochemical staining methods with Ki67 and MDM2 were applied.

## RESULTS

Our results suggest that the sinusoidal lining cells developed as a result of mesodermal cells differentiating by different methods. The mononuclear cells of the lesions were found to be mesenchymal cells with histiocytic characteristics, which was consistent with the literature. The proliferation rate of SABCs were determined to be higher than those of ABCs, considering AgNOR counts, Ki67 proliferation index, and MDM2 results.

## CONCLUSION

All our findings show that SABC has a higher proliferative potential and more aggressive biological behavior. It is possible to consider SABC as a subgroup of ABC, a benign tumor. The question of there is a malignant form of benign ABC still needs to be investigated further.

**Keywords:** Aneurysmal bone cyst; AgNOR; Ki67; MDM2; Solid aneurysmal bone cyst.

Copyright © 2019, Turkish Society for Radiation Oncology

## Introduction

According to the 2013 World Health Organization (WHO) Classification of Tumours of Soft Tissue and Bone, aneurysmal bone cyst (ABC) is a destructive, expansile, benign neoplasm of the bone that consists of multiloculated blood-filled cystic spaces of variable sizes, separated by connective tissue septa containing bland fibroblasts, multinucleated osteoclast-type giant cells, and reactive woven bone.[1]

ABC may arise de novo (primary ABC) or may occur as a secondary post-surgical complication of other benign bone lesions or benign and malignant bone tumors that have undergone hemorrhagic cystic change (secondary ABC).[1-5]

In 1903, Gaylord defined the lesion as an “obscure, pulsating, markedly hemorrhagic tumor of bone” and suggested the term “bone aneurism.”[6] This term was considered to be the first reference to the affection made by Perci-

Received: July 08, 2019

Accepted: July 23, 2019

Online: August 28, 2019

Accessible online at:  
www.onkder.org

**OPEN ACCESS** This work is licensed under a Creative Commons Attribution-NonCommercial 4.0 International License.



Dr. Nihan AKSAKALLI,

İstanbul Üniversitesi,

Onkoloji Enstitüsü,

Tümör Patolojisi,

İstanbul-Turkey

E-mail: aksakallinihan@gmail.com

val Pott.[6] However, the first satisfactory description was given by Else in 1769.[6] A review of the literature shows that this entity was previously known and described under different names by several authors as shown in Table 1.[7-16] The first pathologic and radiographic descriptions of this lesion were presented by Barrie in 1922 under the name of "hemorrhagic osteomyelitis"[9] First cognizance of this condition was taken up by Jaffe and Lichtenstein in 1942 [11], who described two different and distinctive solitary unicameral bone cysts of rather larger sizes as peculiar, blood-containing, cyst-like lesions and designated them as "aneurysmal cysts." The term "aneurysmal bone cyst" was proposed by Lichtenstein in 1950 for this particular lesion.[14] In those years, the lesion was widely accepted as a definite clinicopathological entity. The presence of a malignant form of this condition was claimed only later by some researchers, who designated this form as "malignant aneurysmal bone cyst" (Table 1).[17-20] Nonetheless, Tahsinoğlu et al.[21] strongly proposed the name "aneurysmal bone tumor" for the lesion in 1980, due to its resemblance to the behavior of a tumor rather than an anomaly

or a cyst. These tumor-like features included the cyst's development, radiological features, clinical course, biological behavior, recurrence, and ability to invade epiphyses in suitable conditions. In 1983, Sanerkin et al.[22] defined a type of ABC that is devoid of cystic aneurysm. They suggested the name "solid aneurysmal bone cyst" (SABC), as the lesion had histopathological features similar to the solid areas of ABC, including aneurysmal sinusoids.

In later years, cytogenetic and molecular cytogenetic studies were conducted on benign cystic lesions of bone, some of which claimed to be tumors. In 1999, Kido et al.[23] reported that high telomerase activity was detected in two out of three cases with ABC, which was associated with poor prognosis and had an important role in tumor progression. Moreover, a clonal chromosomal abnormality in the form of t(16q22) (17p13) was detected in all the cases in a cytogenetic study conducted on three ABCs by Panoutsakopoulos et al.[24] in 1999, and they put forward a critical gene on chromosome 16. Sciort et al.[25] detected karyotypic anomalies in the segments of 16q22 and 17p11-13 by cytogenetic research carried out on three ABCs in 2000. With these findings, they reported that ABC could be considered a true neoplasm.

Another study undertaken by Oliveira et al.[26] revealed locus rearrangements in the osteoblast cadherin 11 gene (CDH11) or Ubiquitin Specific Peptidase 6 (USP6) gene in 69% of 52 primary ABC cases, and they observed that some of these cases displayed USP6CDH11 fusion. However, they did not detect these findings in secondary ABC cases. Although the molecular change was not correlated with clinical behavior, they detected a relationship between the localization of the lesion and clinical behavior. In another study conducted by Oliveira et al.[27] that compared ABCs and other tumors of bone, there was reportedly a fusion seen between the promoter region of CDH11 and the entire coding sequence of USP6 in ABC cases. The researchers reported that this t(16;17) (q22; p13) translocation may have caused the recurrence of ABC. It has also been reported that even though CDH11-USP6 fusion can not be observed in some ABCs, the presence of translocation in CDH11 or USP6 could probably indicate the presence of other variant fusion oncogenes. Further, it

**Table 1** Normanclature and history of aneurysmal bone lesions

Authors	Year	Nomanculater and history
<b>Benign</b>		
Percival Pott*	Unkown	"First references"
Else*	1769	"Satisfactory description"
Gentilhomme*	1863	Bone Aneurism
Oehler*	1893	Bone Aneurism
Van Arsdale [7]	1893	Ossifying hematoma'
Bloodgood [8]	1910	Periosteal hematoma
Barrie [9]	1922	Hemorrhagic osteomyelitis"
Ewing**	1940	Aneurysmal giant cell tumor/ Bening bone aneurysm" <sup>iii</sup>
Potts [10]	1940	Subperiosteal Giant Cell Tumor <sup>v</sup>
Jaffe and Lichtenstein [11]	1942	Aneurysmal cyst <sup>v</sup>
Coley and Miller [12]	1942	Atypical giant cell tumor
Shallow and Wagner [13]	1946	Pulsating giant cell tumor
Lichtenstein [14]	1950	Aneurysmal bone cyst <sup>v</sup>
Sherman and Soong [15]	1957	Aneurysmal bone cyst <sup>viii</sup>
Bernier and Bhaskar [16]	1958	Aneurysmal bone cyst <sup>viii</sup>
Tahsinoğlu et al [21]	1980	Aneursymal bone tumor
Sanerkin et al [22]	1983	Solid aneurysmal bone cyst
WHO [1]	2013	Aneurysmal bone cyst <sup>x</sup>
<b>Malign</b>		
Price and Sumner Smith [17]	1966	Malignant bone aneurysm
Clough and Price [18]	1968	Malignant bone aneurysm
Sheldon [19]	1969	Malign aneurysmal bone cyst
Hirst et al [20]	1970	Malign aneurysmal bone cyst

'First identification of such a tumor; "First pathologic and radiologic description; "<sup>iii</sup>Same discussion referring these lesions; "<sup>iv</sup>First definition in the mandible; "<sup>v</sup>First cognizance; "<sup>vi</sup>Proposed name of the lesion; "<sup>vii</sup>Reported radiographic features in the mandible; "<sup>viii</sup>First report of cases of the jaws; "<sup>ix</sup>First formal benign neoplasm definition; "<sup>x</sup>The paper (Oehler. Ueber das sogenannte Knochenaneurysma, Deutsche Zeitschrift für Chirurgie, Leipzig, 1893; xxxvii,525- 539) is not available. Transferred by Gaylord. [6]; "<sup>\*\*</sup>The book (Ewing J. Neoplastic Diseases; a Treatise on Tumors, 4<sup>th</sup> ed. Philadelphia. W. B. Saunders Co. 1940; pp. 323-324) is not available. Transferred by Lichtenstein.[14]

has been suggested that CDH11-USP6 transcription fusion is specific for ABC and that the oncogenic mechanism is mediated by the transcriptional up-regulation of USP6. As a consequence of these molecular studies, the classification of ABC according to the 2002 WHO Classification of Tumours of Soft Tissue and Bone was revised from being a tumor-like condition to a benign neoplasm, according to the 2013 WHO Classification of Tumours of Soft Tissue and Bone.[1]

The solid variant of ABC (SABC) is very rare and is observed in a ratio of 3.4%–7.5% of all ABCs.[28] SABC is seen as a characteristic lytic eccentric lesion with a soap-bubble-type, cortical blow-out appearance in radiographic examinations.[29] It radiologically overlaps with malignant lesions of bone, especially osteosarcoma. In SABC, histologically, a proliferation of mostly spindle-shaped cells, multiple osteoclastic giant cells, and mitotic cells are detected. Yet, no bizarre nuclei, prominent nucleoli, or abnormal mitoses are observed. Generally, reactive ossification is seen with osteoid and trabecular bone matrix formation.[22,29]

In aneurysmal bone lesions (ABL: ABC, SABC), there exist different interpretations exist regarding the sinusoidal lining cells. Although Godfrey et al.[30], Saylam et al.[31], and Ruiter et al.[32] support the idea that these cystic spaces are lined by endothelial cells, some researchers state that the cystic spaces are not lined by endothelial cells [33–37] and that the wall of these cavities do not possess elastic fibers and smooth muscle layers.[38,39] Cells covering these cavities have been advocated to be flattened fibroblasts [35–38], giant cells or endothelial-like cells [39], histiocyte-like cells [40], and rarely osteoclasts.[36] Huvos [29], on the other hand, suggested that the cavities generally lack an endothelial layer, but not always.

Different clinical behaviors of ABLs have been reported. Some of these lesions seemed to be clinically aggressive and more likely to recur. Among these lesions, the cases that behaved like malignant tumors have also been noted. [19] In these circumstances, different prognostic expectations arise for some ABLs.[30] In the literature, there exist different hypotheses regarding the cells of origin lining the cystic spaces or cavities. Therefore, in the current study, we firstly aimed to investigate the biological behavior of ABLs by performing histochemical and immunohistochemical staining of cell cycle regulatory markers and secondly, to reveal the origin of the cells lining the aneurysmal spaces by immunohistochemical staining.

## Materials and Methods

### Sample Collection and Selection Criteria

In the current study, all cases diagnosed as ABLs were retrieved from the archives of the Department of Tu-

mor Pathology of İstanbul University Oncology Institute, from 1989 to 2001. Some of the cases were not suitable to be evaluated technically. Due to the aforementioned problem encountered, only one case of malignant ABC, diagnosed as “aneurysmal bone cyst with nuclear pleomorphism” (ABCNP), was included in this study. In order to obtain an adequate number of ABLs and telangiectatic osteosarcomas (which are very rare), paraffin blocks of these lesions were obtained from other pathology centers. The cases discussed at the Registration Center of Bone and Soft Tissue Tumors of Turkish Oncology Association were also included in the study.

In this research, the lesions that comprised the ABL study group included 30 primary ABCs, 24 solid-type or clinically aggressive ABCs (SABCs), and 1 ABCNP.

Fibrous dysplasia (FD), a benign fibro-osseous lesion and giant cell tumor (GCT), a benign neoplasm, were selected as control groups due to their similarity in biological behaviors to ABCs and SABCs, respectively. Telangiectatic osteosarcoma (TOS), a high-grade malignant tumor composed of blood-filled sinusoids, was also selected as a control group due to its histomorphological similarity to ABCNP. Thus, the control group was made up of 11 FD, 11 GCT, and 20 TOS cases.

Radiological images, treatment protocols, and clinical follow-up data were collected from the archives of five different centers and the collected data were examined in the Tumor Pathology Department of İstanbul University Oncology Institute.

### Sample Preparation and Histological Examination

The most appropriate paraffin blocks with adequate lesions from all paraffin blocks of the material along with the lesions from different centers were selected and included in the study in the Tumor Pathology Department of İstanbul University Oncology Institute.

Sections approximately 5 µm thick were cut and prepared from paraffin blocks, stained with hematoxylin-eosin, and examined under a light microscope.

### Methods

Argyrophilic nucleolar organizer region (AgNOR) (histochemically) and Ki67 and MDM2 primary antibodies (immunohistochemically), were administered to determine the proliferation levels of the lesions in both the study and control groups.

Factor VIII-related antigen (FVIIIIRAg), CD34, and CD68 primary antibodies were applied immunohistochemically to investigate the histogenesis of sinusoidal lining cells in ABLs in the study group.

**AgNOR Technique**

Solution A: 10 g silver nitrate was dissolved in 20 ml deionized water.

Solution B: 0.2 g gelatin powder was dissolved in 10 ml deionized water at 37°C, followed by the addition of 100 µl formic acid. A clear solution was obtained after continuous shaking for 10 minutes at 37°C to completely dissolve the gelatin.

An AgNOR working solution was prepared by mixing solution A with solution B just before the staining procedure. Previously prepared slides were stained and incubated in a dark chamber for 35-45 minutes at room temperature (25°C-30°C). The slides were removed from the staining bath and thoroughly washed in running "deionized" water for 1-5 minutes. Stained slides were dehydrated in graded ethanol, followed by washing in xylene, and were mounted in dibutyl phthalate and xylene.[41]

**Immunohistochemical Staining Technique**

The Ultravision Large Volume Detection System Anti-Mouse and HRP (Ready-to-Use) Kit (Lab Vision Corporation) were used for primary antibodies of FVIIIIRAg/von Willebrand Factor (Endothelial Cell Marker) Ab-2 at a dilution of 1:30, CD34 (Endothelial Cell Marker) Ab-1 at a dilution of 1:50, CD68 (Macrophage Marker) Ab-3 at a dilution of 1:50, Ki67 (Proliferation Marker) Ab-2 at a dilution of 1:50, and MDM2 Ab-1 at a dilution of 1:50. The AEC (Zymed Laboratories) chromogen was used to visualize the reaction. Finally, the sections were counterstained with Mayer's hematoxylin and coverslipped.

**Evaluation of Histochemical and Immunohistochemical Staining**

All slides were examined under light microscopy. Only the mononuclear cells constituting the lesions were evaluated in all groups with proliferation markers. The cases were examined in a double-blind method, without the knowledge of their types and protocol numbers, to avoid subjective evaluation. In all groups, only the existence of staining was evaluated, disregarding the staining intensity. The sections were quantitatively analyzed.

AgNOR: The AgNORs were observed as black dots in the nuclei under light microscopy by using immersion oil. All well-defined discrete dots in the nucleoli were counted as single dots. For each case, the numbers of AgNORs were counted in 100 mononuclear cell nuclei under x1000 magnification in randomly selected areas. AgNOR counts were obtained by calculating the average of all the values.[41]

Ki67: The areas containing the largest number of Ki67-positive cells were selected and the numbers of positive cells with nuclear staining in red-brown by Ki67 were counted in 10 high-power fields (HPFs) (x400) and chosen randomly. For standardization, a 10/10 square scaled ocular was used. Then, the scores were averaged to obtain the Ki67 index (the number of Ki67-positive cells/10 HPFs) in each case.[42]

MDM2: As stated on the datasheet of the producer company, the cells showing as red-brown, predominantly nuclear cells with some cytoplasmic staining were evaluated. The percentages of the positive areas were assessed, regardless of the staining intensity. Each slide was scored independently and blindly by two observers (N.A. and V.O.) and the average of these values was calculated (the rate of MDM2-positive cell percentage/2).

FVIIIIRAg, CD34, and CD68: Slides were examined at low, medium, and high-power magnifications. Mononuclear cells, multinucleated giant cells, sinusoidal lining cells, and cells lining the vessels in the lesion were taken under evaluation. CD34 staining was observed in the membrane and FVIIIIRAg and CD68 stainings were detected in the cytoplasm in a red-brown color. Assessment of the staining was done as positive (+) or negative (-). The intensity and extent of staining were disregarded.

**Statistical Analysis**

The statistical analysis was made with SPSS (Statistical Package for Social Sciences version 21). The data were presented as mean±SD. The data were compared among groups by using Kruskal-Wallis, Mann-Whitney U, and Chi-Square tests. A p-value of <0.05 was considered to be significant.

AgNOR counts, Ki67, and MDM2 expression: The Mann-Whitney U test was used to compare the numerical values among the groups.

FVIIIIRAg, CD34 and CD68 expression: The frequency distributions among the groups of the categorical variables, such as vessels in the lesion, sinusoidal lining cells, mononuclear cells, and giant cells of the lesion were evaluated using Chi-Square tests.

**Results****Characteristics of the Cases**

Age, gender, localization of the lesion, histological diagnosis, and clinical follow-up distributions are shown in Table 2.

Follow-up data of only 15 cases were available in the clinics. Among those, nine had local recurrence and six

had no recurrence. Localization of the recurrent cases is shown in Table 3. Of these, seven cases were diagnosed as SABCs and two cases were diagnosed as ABCs. One ABCNP case had no follow-up record.

**Histogenesis**

Figure 1 shows FVIIIIRAg, CD34, and CD68 expression in the ABC and SABC cases. The histogenetic findings and statistical comparison between ABC and SABC groups are shown in Table 3 along with the histogenetic findings of the ABCNP case. Histogenetic results were observed to be similar in the ABC and SABC groups, with no statistically significant difference between them.

**Proliferation**

AgNOR counts and Ki67 and MDM2 expressions in ABC, SABC, and ABCNP cases are depicted in Figure 2.

**AgNOR Counts**

The AgNOR counts of the ABC, SABC, TOS, GCT, and FD groups and the comparison of AgNOR levels counts among the groups are shown in Table 4. The AgNOR count in the ABCNP case was 22. As there was only one case, no intergroup comparison was made for it. AgNOR

count of ABCNP was detected to be about twice as high as ABC and FD, about one level higher than SABC and GCT, and was closest to that of TOS.

**Ki67 and MDM2 Proliferation Indices**

The Ki67 and MDM2 proliferation indices of the ABC, SABC, TOS, GCT, and FD groups and their intergroup comparisons are demonstrated in Table 4. Ki67 and MDM2 proliferation indices of the ABCNP case were 40 and 95, respectively. As there was only one case, no intergroup comparisons could be made for it. The Ki67 index of ABCNP was higher than that of ABC but lower than that of other groups. However, the MDM2 index of ABCNP was higher than all of the other groups.

**Discussion**

ABC is a locally aggressive, destructive, and recurrent neoplasm with a recurrence rate of 20%–70%. [1] Although many treatment modalities are used for ABC, in general, curettage and bone grafting are preferred. Even after conservative surgery with curettage, the recurrence rate is observed to be unacceptably high (59%–68%). Therefore, according to the anatomical localization of the lesion, cement, high-speed burr, argon beam coagulation, cryotherapy, sclerotherapy, arterial occlusion-embolization, and adjuvant radiotherapy are added to the main treatments in order to prevent local recurrence following curettage. En bloc resection is performed if the lesion has an enlargement in a bone that does not have a function, such as a rib or fibula. [14,29,39,43,44]

GCT of bone is a benign, locally aggressive, primary neoplasm of bone, composed of a proliferation of mononuclear cells, many macrophages, and large osteoclastic giant cells. [45]

FD is a benign medullary fibro-osseous lesion that occurs at a single site in one bone or at multiple sites in multiple bones. [46]

TOS is a high-grade malignant bone-forming neoplasm that consists of large, blood-filled cavities that often show septations. [47]

**Histogenesis**

**Vessels in the Lesions**

According to the literature, the cells lining the vessels in these lesions are reported to be stained immunohistochemically with en-

**Table 2** Gender, age, localization, histological diagnosis, and clinical follow-up distributions of study group patients

Characteristics	Type of histopathology			
	ABC (n=30) (%)	SABC (n=24) (%)	ABCNP (n=1)	Total (n=55) (%)
Gender				
Male	12 (40)	15 (63)	1	28 (51)
Female	18 (60)	9 (37)	0	27 (49)
Age	15	16	13	15
(median; range)	(5-46)	(4-64)		(4-64)
Decades				
1	6 (20)	4 (17)	0	10 (18)
2	16 (53)	11 (46)	1	28 (51)
3	4 (13)	0 (0)	0	4 (7)
4	2 (7)	4 (17)	0	6 (11)
5	2 (7)	3 (13)	0	5 (9)
6	0 (0)	1 (4)	0	1 (2)
7	0 (0)	1 (4)	0	1 (2)
Localizations				
Long bones	15 (50)	16 (67)	1	32 (58)
Flat bones	6 (20)	4 (17)	0	10 (18)
Small tubular bones	4 (13)	2 (8)	0	6 (11)
Spinal bones	4 (13)	1 (4)	0	5 (9)
Craniofacial bones	1 (3)	1 (4)	0	2 (4)
Residive	2	7	-	9

ABC: Aneurysmal bone cyst; SABC: Solid or aggressive aneurysmal bone cyst; ABCNP: Aneurysmal bone cyst with nuclear pleomorphism; n: Case number; %: Percentage

endothelial cell markers, such as polyclonal antibodies FVIIIIRAg, Factor VIII-associated antigen and Lectin UEA, monoclonal antibodies of MAB-BW-200, A-1-43, A-10-33, and CD31.[36,37]

In an ultrastructural study on vascular tumors conducted by Llombart-Bosch et al., it was reported that some immature endothelial cells in the vessels are related to the reticuloendothelial system (liver, spleen and lymph nodes) and may have the ability to perform phagocytosis (hemophagocytosis).[38] In another study, the presence of “histiocytic endothelial cells” were recorded by Rosai et al.[48], who also stated that these cells carry cytoplasmic and nuclear properties of endothelial cells as well as histochemical features that resemble those of histiocytes, which are likely to be an overgrowth of a subtype of endothelial cells seen only in benign and malignant neoplasms.

Moreover, lysosomes that perform functions in the digestion of foreign tissue wastes and metabolism products were detected in most of the endothelial cells under electron microscope.[49]

The CD68 antibody is a 110 kD glycoprotein that is very closely related to or known to be part of lysosomes. Although CD68 is known as a marker of histiocytes be-

cause it contains a large number of lysosomes, it is not specific to cell origin, rather, it is a specific marker for the organelle.[50]

In our study, it was observed that endothelial cell markers of FVIIIIRAg and CD34 stained the vessels of the lesions in all the cases of the ABC and SABC groups. The ABCNP case also showed staining with both antibodies. These findings are consistent with the literature.

It was determined that the cells lining the vessels of the lesion were stained with CD68 in 13% (4/30) of ABC subjects and 17% (4/24) of SABC subjects. CD68 staining was also observed in the ABCNP case. Our findings suggest that staining is probably seen in the vessels of the lesions due to the presence of lysosomes that phagocytize cell debris in the cytoplasm of endothelial cells.

### Sinusoidal Lining Cells

Previous ultrastructural studies conducted on sinusoidal lining cells in ABLs report that endothelial differentiation, pericytes, and smooth muscle cells were not detected in the lining cells and that these cells were shown to have features similar to those of fibroblasts. It was also reported that these cystic spaces were covered with fibrin-coated collagen in some conditions.[33,34,38]

**Table 3** Histogenesis results of study groups

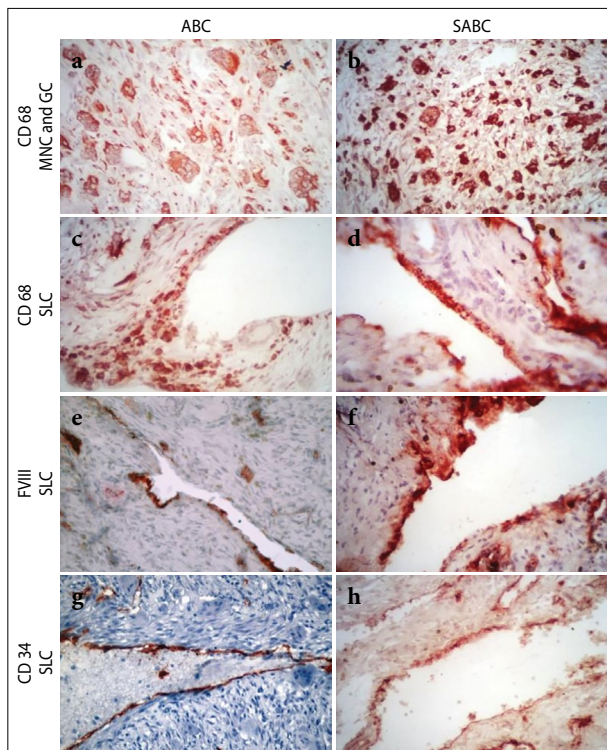
		ABC (n=30) N (%)		SABC (n=24) N (%)		ABCNP (n=1)	
Cell	IHC	+	-	+	-	+	-
MNC	FVIII	4 (13)	26 (87)	5 (21)	19 (79)	0	0
	CD34	0 (0)	30 (100)	1 (4)	23 (96)	0	0
	CD68	30 (100)	0 (0)	24 (100)	0	1	0
GC	FVIII	1 (3)	29 (97)	0 (0)	24 (100)	0	0
	CD34	0 (0)	30 (100)	0 (0)	24 (100)	0	0
	CD68	30 (100)	0 (0)	24 (100)	0 (0)	1	0
SLC	FVIII	18 (60)	12 (40)	16 (67)	8 (33)	0	0
	CD 34	15 (50)	15 (50)	12 (50)	12 (50)	0	0
	CD 68	29 (97)	1 (3)	20 (83)	4 (17)	1	0
VL	StV FVIII	30 (100)	0 (0)	24 (100)	0 (0)	1	0
	StV CD 34	30 (100)	0 (0)	24 (100)	24 (0)	1	0
	StV CD 68	4 (13)	26 (87)	4 (17)	20 (83)	1	0

ABC: Aneurysmal bone cyst; SABC: Solid or aggressive aneurysmal bone cyst; ABCNP: Aneurysmal bone cyst with nuclear pleomorphism; MNC : Mononuclear cell, GC: Giant cell; SLC: Sinusoidal lining cell; VL: Veins in the lesion; n: Case number; N: Staining cell number; +: Staining; -: No staining

**Table 4** AgNOR counts, Ki67 and MDM2 results in study and control groups with statistical comparison between groups

Study and control groups	AgNOR* mean±SD (min.-max.)	Ki67* mean±SD (min.-max.)	MDM2* mean±SD (min.-max.)
ABC (n=30)	5±1 (3.3-7)	30±17 (2.5-68.3)	59±23 (10-95)
SABC (n=24)	9±2 (6.8-13.4)	65±55 (9.7-202.8)	72±19 (35-97)
TOS (n=20)	27±4 (17.5-35.2)	103±64 (15.3-261.2)	79±14 (40-95)
GCT (n=11)	9±1 (7.2-11.2)	74±34 (50.4-160.4)	59±25 (10-95)
FD (n=11)	3±0 (2.8-4.3)	59±51 (8.5-77.1)	52±16 (25-85)

\*p<0.01; ABC: Aneurysmal bone cyst; SABC: Solid or aggressive aneurysmal bone cyst; ABCNP: Aneurysmal bone cyst with nuclear pleomorphism; n: Case number



**Fig. 1.** Selective immunohistochemical pictures of ABC and SABC. (a, b) CD68 immunoreactivity of mononuclear cells and giant cells (CD68X400) in ABC & SABC, respectively. (c, d) CD68 immunoreactivity of sinusoidal lining cells (CD68x400) in ABC & SABC, respectively. (e, f) FVIII immunoreactivity of sinusoidal lining cells (FVIIIx400) in ABC & SABC, respectively. (g, h) CD34 immunoreactivity of sinusoidal lining cells (CD34x400) in ABC & SABC, respectively.

Some immunohistochemical studies conducted with many polyclonal and monoclonal endothelial cell markers and endothelial basal membrane markers that are used for cells lining large cystic spaces in ABC reported that none of these cells were stained with these markers. [33,34,37] On the other hand, in the study undertaken by Shannon et al.[40], it was reported that only a few cases stained for FVIIIIRAg, and in another study conducted by Szendroi et al.[36] it was revealed that only a few number of cells were positive for CD31.

Some studies regarding sinusoidal lining cells in ABC cases where histiocytic cell markers, such as  $\alpha 1$ -antitrypsin,  $\alpha 1$ -antichymotrypsin, anti-lysosome, and CD68 were used immunohistochemically, reported that some lining cells stained for these markers.[34,40] Some researchers concluded that these cells could be regarded as histiocytes at different developmental stages.[33,40] On the contrary, Vollmer et al.[37] reported that histi-

ocytic cell markers did not display immunoreactivity in the lining cells of ABCs.

In the literature, some researchers have reported that some sinusoidal lining cells are actually flattened fibroblasts.[33,36,37]

In our study, the sinusoidal lining cells were stained with FVIIIIRAg in the ABC group at a rate of 60% (8/30) and in the SABC group with a rate of 67% (16/24). CD34 staining was observed at a rate of 50% (15/30 in ABCs, 12/24 in SABCs) in both groups. In the ABCNP case (n=1), no staining was observed with either of the antibodies. CD68 staining rates were detected to be 97% (29/30) in ABC group and 83% (20/24) in SABC group. ABCNP (n=1) also showed CD68 staining. Compared with the literature data, our findings were consistent with the findings of Shannon et al.[40] and Szendroi et al.[36] It was observed that a portion of the sinusoidal lining cells were of endothelial origin and a bigger portion of the lining cells were of histiocytic origin. Our results suggest that the sinusoidal lining cells probably originated by the differentiation of mesodermal cells into different cell lineages (endothelial, histiocytic, etc.).

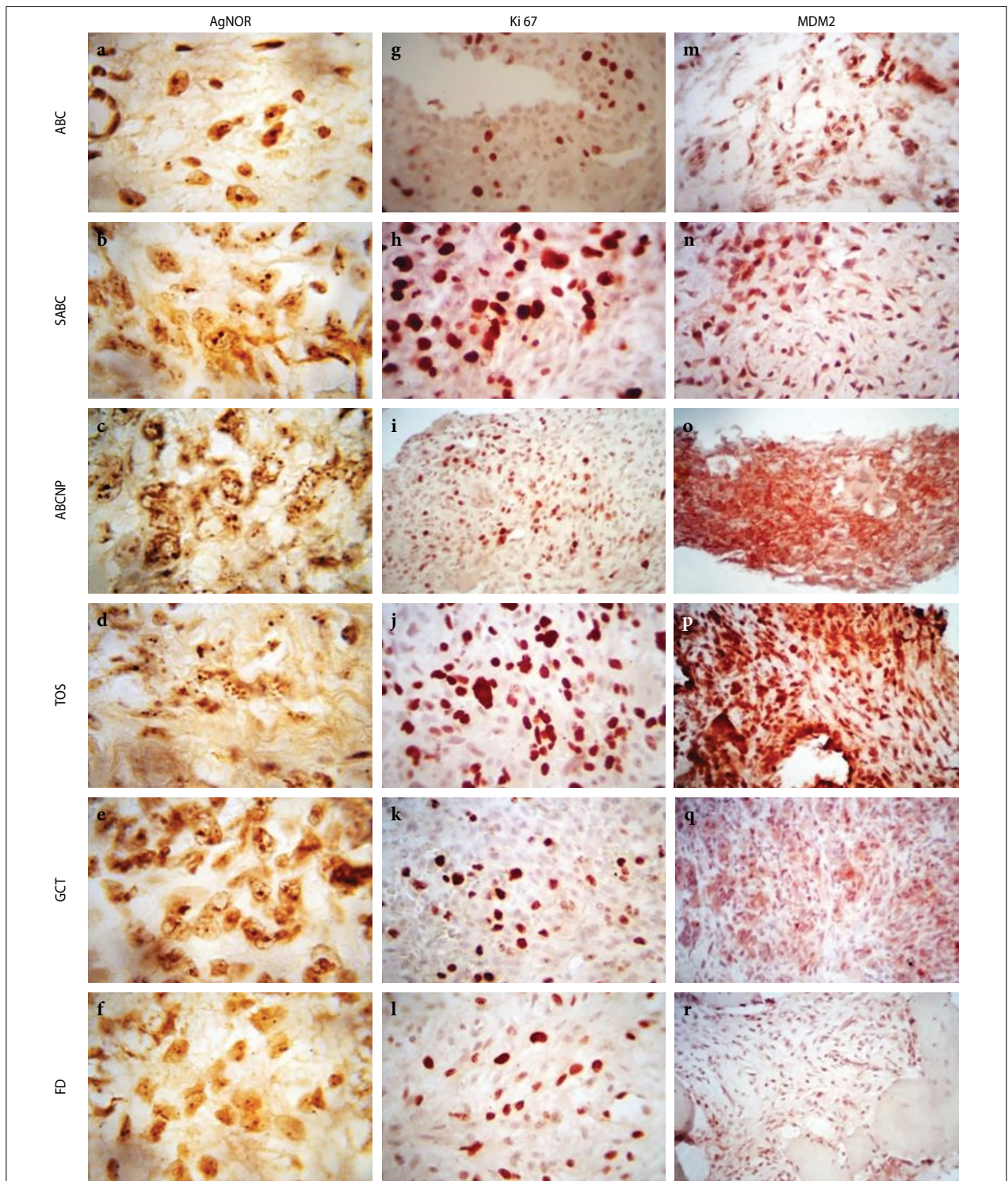
#### Mononuclear Cells of the Lesions

Aho et al.[33] observed that some mononuclear cells forming the lesion stained strongly with FVIIIIRAg in a study where 7 ABC cases were investigated. They stated that staining did not prove that the cells were endothelial in origin, since thrombocytes and mast cells also harbor FVIIIIRAg. Therefore, it was suggested these positively stained cells were likely to be mast cells.

In the current study, mononuclear cells forming the lesion were stained with FVIIIIRAg in 13% (4/30) of the ABC group and 21% (5/24) of the SABC group. With CD34, none of the cases in the ABC group were stained, yet only one (7%) out of 24 cases was positive in the SABC group. No staining was detected with either of the antibodies in the ABCNP case. Therefore, the results of our study are consistent with the findings of Aho et al.[33]

Many researchers have reported that mononuclear cells forming the lesions were stained with various histiocytic markers.[34,36,37] According to the study conducted by Alles et al.[34] with electron microscope, the mononuclear cells forming the lesions were of two types; some of them carrying the cytoplasmic organelles of fibroblastic cells and others were Golgi apparatus and lysosome-bearing typical histiocytic cells. For this reason, the mononuclear cells forming the lesion were thought to be histiocytic cells at different stages of differentiation.

Our findings demonstrated that all the mononuclear cells (100%) forming the lesions were stained with



**Fig. 2.** Representative pictures of proliferations stainings in study and control groups. (a-f) show representative areas with AgNOR stain in ABC, SABC, ABCNP, TOS, GCT, and FD, respectively, (AgNORx1000). (g-l) show representative areas of Ki67 immunoreactivity in ABC (Ki67x200), SABC (Ki67x400), ABCNP (Ki67x100), TOS (Ki67x400), GCT (Ki67x200), and FD (Ki67x200), respectively. (m-r) show representative areas at MDM2 immunoreactivity in ABC (MDM2x200), SABC (MDM2x200), ABCNP (MDM2x100), TOS (MDM2x200), GCT (MDM2x200), and FD (MDM2x200), respectively.



CD68 in both the ABC and SABC groups. The ABCNP case (n=1) also stained with CD68. These results are in consistent with the literature.

### **Giant Cells of the Lesion**

It has been reported that giant cells in ABCs are immunohistochemically stained with  $\alpha$ 1-antitrypsin,  $\alpha$ 1-antichymotrypsin, anti-lysosome, and CD68 primary antibodies.[34,36] Vollmer et al.[37] reported rare staining with monoclonal endothelial marker A-1-43 in the giant cells of the lesion.

In our study, 97% of the giant cells in the ABC group (n=30) were not stained with FVIIIIRAg and only one (3%) case reacted to this marker. None of the cases in the SABC group stained for FVIIIIRAg. None of the cases in either ABC or SABC groups showed staining with CD34. There was no staining with either of the antibodies in the ABCNP case. However, all cases in both the ABC and SABC groups were stained with CD68. Immunoreactivity with CD68 was detected in the ABCNP case. These findings are in harmony with previously reported data.

In the immunophenotypic examination regarding the histogenesis of the ABL study group, no statistically significant difference was detected between the ABC (n=30) and the biologically more aggressive SABC (n=24) and ABCNP (n=1) groups.

### **Proliferation**

#### **AgNOR**

Ribosomal genes that are located in particular sites of chromosomes are defined as nucleolar organizer regions (NORs). In normal cells, the AgNORs are tightly packed in the nucleoli and are indiscernible. In rapidly proliferating cells such as neoplastic cells, nucleolar disaggregation may take place, resulting in dispersion of individual AgNOR. Using silver staining techniques, the interphase NORs can be visualized by both electron and light microscopes.[51] The AgNOR count is an important index for assessing proliferating cells.[52]

Recent studies show that AgNORs are significantly higher in malignant cells than in normal cells. In studies conducted on AgNOR-related benign and malignant neurogenic tumors, carcinomas, and premalignant lesions, increased proliferative activity was correlated with increased AgNOR levels. Moreover, AgNOR counts were found to predict biological behavior independent of cell differentiation in malignant tumors and the AgNOR index was shown to be correlated with the relationship between the clinical and histological stage. It has also been reported that AgNOR counts have an effect on the prognosis and are more reliable than the histological criteria to determine the clinical course of a tumor.[41,53-56]

In the current study, when AgNOR counts in ABLs were examined, the following results were obtained: AgNOR counts of the SABC group (mean=9, n=24) were higher than those of the ABC group (mean=5, n=30), and this difference was statistically significant between the two groups (p=0.000). When the study groups were compared with the control groups, AgNOR counts of the SABC group (mean=9, n=24) were higher than those of the FD group (mean=3, n=11), and this difference was statistically significant between the two groups (p=0.00). The SABC and GCT groups had the same AgNOR counts. The mean value of AgNOR counts of TOS was 27 (n=20). This value was found to be 22 in the ABCNP case (n=1).

#### **Ki67**

The Ki67 monoclonal antibody reacts with Ki67 antigen, a nuclear antigen found only in proliferating cells. This antigen was found to be expressed in all phases of the cell cycle except for the G0 phase. It is not expressed in G0, early G1, and in the middle of G1 phase. Expression levels increase toward the end of the cell cycle and it is expressed in late G1, S, G2, and M phase. Ki67, as a marker of cell proliferation activity, may be the indicative of any time in the cell cycle, yet very strong expressions are particularly seen in the cells at G2 and M phases.[57-59]

In the studies regarding soft tissue sarcoma cases where Ki67 was used, it has been reported that there is a correlation between Ki67 reactivity in tumor cells and the clinical course of patients. The Ki67 proliferation index is much more sensitive and reliable than the mitotic activity and is used as a prognostic factor. There is a strong relationship between metastasis and high Ki67 index; the Ki67 index reflects the biological behavior of tumors and a high Ki67 index indicates increased risk of tumor recurrence. Based on these facts, Ki67 can give useful information about survival rates.[42,60,61]

In this study, when Ki67 proliferation indices in ABLs were examined, the following results were obtained: Ki67 index of the SABC group (mean=65, n=24) was higher than that of the ABC group (mean=30, n=30) and this difference was statistically significant between these two groups (p=0.008). When the study groups were compared with the control groups; Ki67 index of the FD group (mean=59, n=11) was higher than that of the ABC group (mean=30, n=30) and this difference was not statistically significant between these two groups (p=0.87). Ki67 index of the SABC group (mean=65, n=24) was higher than that of the FD group (mean=59, n=11) and this difference was not statistically significant between these two groups (p=0.09). Ki67 index of the GCT group (mean=74, n=11) was higher than that of the SABC group (mean=65, n=24)

and this difference was not statistically significant between these two groups ( $p=0.37$ ). Ki67 proliferation index of ABCNP was 40 ( $n=1$ ).

## MDM2

A cellular phosphoprotein MDM2 (the product of murine double minute 2 gene) binds to both wild-type and mutant forms of the p53 gene and the retinoblastoma protein. It inhibits the transcriptional activity of p53 and this inhibition has been shown to be amplified preferentially in sarcomas.[62] Overexpression of MDM2 has clinical implications in some carcinomas, sarcomas, and leukemias that are related to poor outcome, adverse prognostic factors, poor treatment response, and metastatic potential.[63]

In studies on osteosarcoma, the relationship between MDM2 amplification, relapse, and/or metastasis was found to be significant in showing the importance of MDM2 amplification in determining the tumor stage and prognosis.[62,64]

In the current study, the proliferation index of MDM2 of SABC group (mean=72,  $n=24$ ) was higher than that of ABC (mean=59,  $n=30$ ), FD (mean=52,  $n=11$ ) and GCT (mean=59,  $n=11$ ) groups. While statistically significant differences between the SABC and ABC groups ( $p=0.035$ ) and the SABC and FD groups ( $p=0.00$ ) were detected, no statistically significant difference was observed between the SABC and GCT groups ( $p=0.142$ ). The proliferation index of MDM2 of the SABC group was closer to the MDM2 index of the TOS group (mean=79,  $n=20$ ). Although it is not possible to make an interpretation based on a single case, it was noteworthy that MDM2 expression in ABCNP was higher than that of TOS. Our findings are in consistent with the literature.

Considering the AgNOR counts and the proliferation indices of Ki67 and MDM2, it was observed that the SABC proliferation rate is higher than ABC. This finding is compatible with the characteristics of SABC that clinically shows the most locally aggressive biological behavior among the ABCs.

As a result of the progression of molecular cytogenetic researches, which were insufficient in the number for that period, ABC was finally accepted as a tumor in the 2013 WHO Classification of Tumours of Soft Tissue and Bone, confirming our prior research findings.

There have been many molecular cytogenetic studies conducted on this subject. In the literature, in 2018, Li et al.[65] reported that they found USP6 gene rearrangement in SABC as well, while Šekoranja et al.[66] reported that the most common fusion partner of USP6 was the CDH11 gene on ABC; however, there have also been other fusion partners such as SPARC-USP6 fusion

in SABC. Future molecular studies on SABCs will clarify these issues.

Limitations of the study: The presence of nuclear pleomorphism in the ABC, inadequacy of the number of cases included in the study due to the rarity of clinically aggressive ABCs (SABC and telangiectatic osteosarcomas), and the lack of the records of the follow-up of the cases in clinics are the major limitations of this study.

## Conclusion

The subgroups of ABC, which has been classified as a benign neoplasm, are not identified in the 2013 WHO Classification of Tumours of Soft Tissue and Bone. As a result of our study, it has been shown that ABC has different forms such as SABC and ABCNP, which exhibit different clinical behaviors. In this study, the results obtained regarding the proliferation potentials supported the fact that SABCs show more aggressive biological behavior than ABCs clinically, radiologically, and histologically. Therefore, we suggest that this finding should be taken into consideration in the treatment management of SABC cases.

Due to the aggressive biological behavior of SABC, the inclusion of this entity as a subgroup of ABC should be re-evaluated. The probability of presence of a malignant form of ABC, defined as a benign neoplasm, is still an issue of discussion and open to debate. Malignant lesions with morphological features similar to ABCNP are interpreted as telangiectatic osteosarcomas. It is necessary to investigate whether ABCNP, which was included in our study, is a malignant form of aneurysmal bone tumor or not. The rarity of these lesions was regarded as the major limitations of the study. This issue can be overcome by conducting more number of multicentric studies at molecular levels.

**Aknowledgements:** The authors thank Dr. Gülçin Erseven, Dr. Canan Alatli, Dr. Ayla Özveren, Dr. Semra Dölek Güler, Cevriye Özekmekçi, Dr. Rian Disci, Dr. Nadir Arıcan, Dr. Gülçin Başdemir, Dr. Sergülen Dervişoğlu, Dr. Bilge Bilgiç, Dr. Murat Hız, Dr. Harzem Göker, Dr. Nil Molinas Mandel and Dr. Sibel Perçinel for valuable consideration of the cases. In the memory of late Dr. Melih Tahsinoglu.

**Peer-review:** Externally peer-reviewed.

**Conflict of Interest:** The authors declare no competing financial interest.

**Financial Support:** This work was supported by the Research Foundation of Istanbul University. Project number: T-807/07032000.

**Authorship contributions:** Concept – N.A.; Design – N.A., V.O.; Supervision – V.O.; Materials – N.A.; Data collection

&/or processing – N.A.; Analysis and/or interpretation – N.A., V.O.; Literature search – N.A.; Writing – N.A.; Critical review – V.O.

## References

1. Nielsen GP, Fletcher JA, Oliveira AM. Aneurysmal bone cyst. In: Fletcher CDM, Bridge JA, Hogendoorn PCW, Mertens F, editors. WHO classification of tumours of soft tissue and bone. 4th ed. Lyon: IARC; 2013. p. 348–9.
2. Robinson PD. Aneurysmal bone cyst: A hybrid lesion? *Br J Oral Maxillofac Surg* 1985;23(3):220–6.
3. Sakkars RJB, van der Heul RO, Kroon HM, Taminiau AH, Hogendoorn PC. Late malignant transformation of a benign giant-cell tumor of bone. *J Bone Joint Surg Am* 1997;79(2):259–62.
4. Levy WM, Miller AS, Bonakdarpour A, Aegerter E. Aneurysmal bone cyst secondary to other osseous lesions. Report of 57 cases. *AJCP* 1975;63(1):1–8.
5. Martinez V, Sissons HA. Aneurysmal bone cyst: A review of 123 cases including primary lesions and those secondary to other bone pathology. *Cancer* 1988;61(11):2291–304.
6. Gaylord HR. On the pathology of so-called bone aneurysms. *Ann Surg* 1903;37(6):834–47.
7. Van Arsdale WW. Ossifying hematoma. *Ann Surg* 1893;18(1):8–17.
8. Bloodgood JC. I. Benign Bone Cysts, Ostitis Fibrosa, Giant-Cell Sarcoma and Bone Aneurism of the Long Pipe Bones: A Clinical and Pathological Study with the Conclusion that Conservative Treatment is Justifiable. *Ann Surg* 1910;52(2):145–85.
9. Barrie G. Hemorrhagic osteomyelitis. *J Bone Joint Surg Oct* 1922;4(4):653–71.
10. Potts WJ. Subperiosteal giant-cell tumor. *J Bone Joint Surg.* 1940;22(2):417–20.
11. Jaffe HL, Lichtenstein L. Solitary unicameral bone cyst, with emphasis on the roentgen picture, the pathologic appearance and the pathogenesis. *Arch Surg* 1942;44(6):1004–25.
12. Coley BL, Miller LE. Atypical giant cell tumor. *Amer J Roentgenol* 1942;47:541–48.
13. Shallow TA, Wagner FB Jr. Pulsating benign giant cell tumors of bone. *Arch Surg* 1946;52:661–76.
14. Lichtenstein L. Aneurysmal bone cyst. A pathological entity commonly mistaken for giant-cell tumor and occasionally for hemangioma and osteogenic sarcoma. *Cancer* 1950;3(2):279–89.
15. Sherman RS, Soong KY. Aneurysmal bone cyst: Its roentgen diagnosis. *Radiology* 1957;68(1):54–64.
16. Bernier JL, Bhaskar SN. Aneurysmal bone cysts of mandible. *Oral Surg Oral Med Oral Pathol* 1958;11(9):1018–28.
17. Price CHG, Sumner-Smith G. "Malignant bone aneurysm" in a dog: An unusual example of osteosarcoma. *British Veterinary Journal* 1966;122(2):51–4.
18. Clough JR, Price CH. Aneurysmal bone cysts. Review of twelve cases. *J Bone Joint Surg Br* 1968;50(1):116–27.
19. Sheldon AJ. Malign aneurysmal bone cyst: A new tumor of man and animals. *The American association of Pathologists and Bacteriologists Scientific Proceedings. American Journal of Pathology* 1969; 55: 28a.
20. Hirst E, McKellar CC, Ellis JM, Viner Smith K. Malign aneurysmal bone cyst. *Proceedings and reports of councils and associations. J Bone Joint Surg* 1970;52B:791.
21. Tahsinoğlu M, Çöloğlu AS, Bilge N, Tenekecioğlu Y, Kuzgun Ü, Kayakıran T, et al. Aneurysmal bone cyst. *Acta Orthopædica et Travmatologica Turcica* 1980;14(2):7–23.
22. Sanerkin NG, Mott MG, Roylance J. An unusual intraosseous lesion with fibroblastic, osteoclastic, osteoblastic, aneurysmal and fibromyxoid elements: "Solid" variant of aneurysmal bone cyst. *Cancer* 1983;51(12):2278–86.
23. Kido A, Schneider-Stock R, Hauptmann K, Roessner A. Telomerase activity in benign bone tumors and tumor-like lesions. *Pathol Res Pract* 1999;195:753–7.
24. Panoutsakopoulos G, Pandis N, Kyriazoglou I, Gustafson P, Mertens F, Mandahl N. Recurrent t(16;17)(q22;p13) in aneurysmal bone cysts. *Genes Chromosomes Cancer* 1999;26(3):265–6.
25. Sciot R, Dorfman H, Brys P, Dal Cin P, De Wever I, Fletcher CD, et al. Cytogenetic-morphologic correlations in aneurysmal bone cyst, giant cell tumor of bone and combined lesions. A report from the CHAMP study group. *Mod Pathol* 2000;13(11):1206–10.
26. Oliveira AM, Perez-Atayde AR, Inwards CY, Medeiros F, Derr V, Hsi BL, et al. USP6 and CDH11 oncogenes identify the neoplastic cell in primary aneurysmal bone cysts and are absent in so-called secondary aneurysmal bone cysts. *Am J Pathol* 2004;165(5):1773–80.
27. Oliveira AM, Hsi BL, Weremowicz S, Rosenberg AE, Dal Cin P, Joseph N, et al. USP6 (Tre2) fusion oncogenes in aneurysmal bone cyst. *Cancer Res* 2004;64(6):1920–23.
28. Bertoni F, Bacchini P, Capanna R, Ruggieri P, Biagini R, Ferruzzi A, et al. Solid variant of aneurysmal bone cyst. *Cancer* 1993;71(3):729–34.
29. Huvos AG. Bone Tumors. Diagnosis, Treatment, and Prognosis. 2nd ed. Philadelphia: W.B. Saunders, 1991.
30. Godfrey LW, Gresham GA. The natural history of aneurysmal bone cyst. *Proc R Soc Med* 1959;52:900–5.
31. Saylam A, Böke E, Bozer AY, Kutkam T. Benign osteoblastoma and aneurysmal bone cyst. *Hacettepe Bull Med Surg* 1972;5(4):172–77.
32. Ruitter DJ, van Rijssel TG, van der Velde EA. Aneurysmal bone cysts: A clinicopathological study of 105 cases. *Cancer* 1977;39(5):2231–9.
33. Aho HJ, Aho AJ, Pelliniemi LJ, Ekfors TO, Foidart JM. Endothelium in aneurysmal bone cyst. *Histopathology* 1985;9(4):381–87.
34. Alles JU, Schulz A. Immunocytochemical markers (endothelial and histiocytic) and ultrastructure of primary aneurysmal bone cysts. *Hum Pathol* 1986;17(1):39–45.
35. Schajowicz F. Tumors and Tumorlike Lesions of Bone and Joints. New York: Springer-Verlag, 1981.
36. Szendroi M, Arato G, Ezzati A, Hüttl K, Szavcsur P. Aneurysmal bone cyst: Its pathogenesis based on angiographic, immunohistochemical and electron microscopic studies. *Pathol Oncol Res* 1998;4(4):277–81.

37. Vollmer E, Roessner A, Lipecki KH, Zwadlo G, Hagemeyer HH, Grundmann E. Biologic characterization of human bone tumors. *Virchows Arch B Cell Pathol Incl Mol Pathol* 1987;53(1):58–65.
38. Llombart-Bosch A, Peydro-Olaya A, Pellin A. Ultrastructure of vascular neoplasms. A transmission and scanning electron microscopical study based upon 42 cases. *Path Res Pract* 1982;174:1–41.
39. Tillman BP, Dahlin DC, Lipscomb PR, Stewart JR. Aneurysmal bone cyst: An analysis of ninety- five cases. *Mayo Clin Proc* 1968;43(7):478–95.
40. Shannon P, Bédard Y, Bell R, Kandel R. Aneurysmal cyst of soft tissue: Report of a case with serial magnetic resonance imaging and biopsy. *Hum Pathol* 1997;28(2):255–7.
41. Doğan Ö. Nöroblastom-Gangliyonöroblastom-Gangliyonörom tümör serisinde AgNOR yöntemi. İ.Ü. İstanbul Tıp Fakültesi Patoloji Anabilim Dalı (Uzmanlık Tezi) İstanbul; 1991.
42. Ueda T, Aozasa K, Tsujimoto M, Ohsawa M, Uchida A, Aoki Y, et al. Prognostic significance of Ki-67 reactivity in soft tissue sarcomas. *Cancer* 1989;63(8):1607–11.
43. Campanacci M. Bone and Soft Tissue Tumors. Clinical Features, Imaging, Pathology and Treatment. 2nd ed. Italy: Springer-Verlag Wien; 1999.
44. Park HY, Yang SK, Sheppard WL, Hegde V, Zoller SD, Nelson SD, et al. Current management of aneurysmal bone cysts. *Curr Rev Musculoskelet Med* 2016;9(4):435–44.
45. Athanasou NA, Bansai M, Forsyth R, Reid RP, Sapi Z. Giant cell tumour of bone. In: Fletcher CDM, Bridge JA, Hogendoorn PCW, Mertens F, editors. WHO Classification of Tumours of Soft Tissue and Bone. 4th ed. Lyon: IARC;2013. p. 321–4.
46. Siegal GP, Bianco P, Dal Cin P. Fibrous dysplasia. In: Fletcher CDM, Bridge JA, Hogendoorn PCW, Mertens F, editors. WHO Classification of Tumours of Soft Tissue and Bone. 4th ed. Lyon: IARC; 2013. p.352–3.
47. Oliveira AM, Okada K, Squire J. Telangiectatic osteosarcoma. In: Fletcher CDM, Bridge JA, Hogendoorn PCW, Mertens F, editors. WHO Classification of Tumours of Soft Tissue and Bone. 4th ed. Lyon: IARC;2013.p.289–90.
48. Rosai J, Gold J, Landy R. The histiocytoid hemangiomas. A unifying concept embracing several previously described entities of skin, soft tissue, large vessels, bone and heart. *Hum Pathol* 1979;10(6):707–30.
49. Gallagher PJ. Blood vessels. In: Sternberg SS, editor. *Histology for Pathologists*. 2nd ed. Philadelphia: Lippincott-Raven; 1997. p.736–85.
50. Folpe AL, Gown AM. Immunohistochemistry for analysis of soft tissue tumors. In: Weiss SW, Goldblum JR, editors. *Enzinger and Weiss's Soft Tissue Tumors*. 4th ed. St. Louis: Mosby; 2001.p.137–87.
51. Trere D, Farabegoli F, Cancellieri A, Ceccarelli C, Eusebi V, Derenzini M. AgNOR area in interphase nuclei of human tumours correlates with the proliferative activity evaluated by bromodeoxyuridine labelling and Ki67 immunostaining. *J Pathol* 1991;165(1):53–9.
52. Funayama Y, Sasano H, Suzuki T, Tamura M, Fukaya T, Yajima A. Cell turnover in normal cycling human ovary. *J Clin Endocrinol Metabol* 1996;81(2):828–34.
53. Rajerdan R, Nair SM. Silver-binding nucleolar organizer region proteins as a possible prognostic indicator in oral submucous fibrosis. *Oral Surg Oral Med Oral Pathol* 1992;74(4):481–6.
54. De Rosa G, Staibano S, Barra E, Zeppa P, Salvatore G, Vetrani A, et al. Nucleolar organizer regions in aggressive and nonaggressive basal cell carcinoma of the skin. *Cancer* 1992;69(1):123–6.
55. Chomette GP, Auriol MM, Labrousse F, Vaillant JM. Mucoepidermoid tumors of salivary glands: Histoprostic value of NORs stained with AgNOR technique. *J Oral Pathol Med* 1991;20(3):130–2.
56. Sano K, Takahashi H, Fujita S, Inokuchi T, Pe MB, Okabe H, et al. Prognostic implication of silver-binding nucleolar organizer regions (AgNORs) in oral squamous cell carcinoma. *J Oral Pathol Med* 1991;20(2):53–6.
57. Quinn CM, Wright NA. The clinical assesment of proliferation and growth in human tumours: Evaluation of methods and applications as prognostic variables. *J Pathol* 1990;160(2):93–102.
58. Scholzen T, Gerdes J. The Ki-67 Protein: From the know and unknow. *J Cell Physiol* 2000;182(3):311–22.
59. Sales Gil R, Vagnarelli P. Ki 67: More Hidden behind a 'Classic Proliferation Marker'. *Trends Biochem Sci* 2018;43(10):747–8.
60. Choong PFM, Akerman M, Willen H, Andersson C, Gustafson P, Alvegard T, et al. Expression of proliferating cell nuclear antigen (PCNA) and Ki-67 in soft tissue sarcoma. Is prognostic significance histotype- spesific? *APMIS* 1995;103(1):797–805.
61. Antonescu CR, Leung DH, Dudas M, Ladanyi M, Brennan M, Woodruff JM, et al. Alteration of cell cycle regulators in localized synovial sarcoma. A multifactorial study with prognostic implications. *Am J Pathol* 2000;156(3):977–83.
62. Lonardo F, Ueda T, Huvos AG, Healey J, Ladanyi M. P53 and MDM2 alterations in osteosarcomas. Correlation with clinicopathologic features and proliferative rate. *Cancer* 1997;79(8):1541–7.
63. Moller MB, Nielsen O, Pedersen NT. Oncoprotein MDM2 overexpression is associated with poor prognosis in distinct non- hodgkin's lymphoma entities. *Mod Pathol* 1999;12(11):1010–6.
64. Ragazzini P, Gamberi G, Benassi MS, Orlando C, Sestini R, Ferrari C, et al. Analysis of SAS gene and CDK4 and MDM2 proteins in low- grade osteosarcoma. *Cancer Detect Prev* 1999;23(2):129–36.
65. Li HR, Tai CF, Huang HY, Jin YT, Chen YT, Yang SF. USP6 gene rearrangement differentiates primary paranasal sinus solid aneurysmal bone cyst from other giant cell-rich lesions: report of a rare case. *Hum Pathol* 2018;76:117–21.
66. Šekoranja D, Boštjančič E, Salapura V, Mavčič B, Pižem J. Primary aneurysmal bone cyst with a novel SPARC-USP6 translocation identified by next-generation sequencing. *Cancer Genet* 2018;228-229:12–6.