



Sarcoidosis Mimicking Mediastinal Lymph Node Metastases of Cervix Carcinoma: An Unusual Association

Yassir BENAMEUR,^{1,2} Salah Nabih OUERİAGLİ,^{1,2} Omar AIT SAHEL,^{1,2} Abderrahim DOUDOUH^{1,2}

¹Department of Nuclear Medicine, Mohamed V Military Teaching Hospital, Rabat, Morocco

²Mohammed V University (UM5) Faculty of Medicine and Pharmacy, Rabat, Morocco

SUMMARY

Sarcoidosis is a multisystem chronic inflammatory condition of unknown etiology characterized by noncaseous epithelioid cell granulomas. Sarcoidosis can involve any organ but, bilateral well-defined, the most common findings are the enlargement of the symmetric hilar and right paratracheal lymph nodes. The relationship between sarcoidosis and malignancy is poorly defined and the simultaneous coexistence of sarcoidosis and cervix carcinoma has been rarely reported, an unfortunate consequence of the presence of both entities in the same patient is the harmful probability of misdiagnosis. The case studied illustrates an unusual presentation of sarcoidosis that mimicked mediastinal and hilar lymphatic metastases of cervix carcinoma on [¹⁸F]-Fluorodeoxyglucose (¹⁸F-FDG) positron-emission tomography (PET) combined with computed tomography (CT) realized for staging of the cancer. Through the present case, sarcoidosis should be considered when FDG-PET/CT shows intense FDG uptake in non-regional swollen lymph nodes; whenever it is possible a biopsy of the suspected metastatic site should always be performed, in order to avoid excessive or inappropriate treatment.

Keywords: Cervix cancer; FDG-PET/CT; positron-emission tomography and computed tomography; sarcoidosis.

Copyright © 2021, Turkish Society for Radiation Oncology

Introduction

[¹⁸F]-Fluorodeoxyglucose (¹⁸F-FDG) positron-emission tomography (PET) is widely used in the management of a variety of malignancies with excellent overall accuracy and success. However; the main limitation of the method is the failure in the discrimination between malignant and inflammatory or infectious lesions, therefore, benign hypermetabolic lymphadenopathy can mimic the appearance of cancerous lymphadenopathy. Only histological evaluation can solve this dilemma.

Several case reports and case series have been published describing the coexistence of sarcoidosis and malignancy. Although no definite causal relationship

has been yet identified yet, sarcoidosis is usually to be considered in differential diagnosis in patients with present or previous malignancies.

This report describes an unusual case of cervix carcinoma associated with sarcoidosis that mimicked mediastinal and hilar lymph node metastases on an FDG-PET/CT study for staging of the cancer.

Case Report

The patient, a 52-year-old female, P3L3, with no significant past medical record, postmenopausal for 6 years, presented to gynecological department with post-coital bleeding and bilateral lower limb pain. On examination, it was seen that there was a bulky pro-

Received: August 05, 2020

Accepted: November 02, 2020

Online: November 27, 2020

Accessible online at:
www.onkder.org

OPEN ACCESS This work is licensed under a Creative Commons Attribution-NonCommercial 4.0 International License.



Dr. Yassir BENAMEUR

Department of Nuclear Medicine,
Mohamed V Military Teaching Hospital,
Rabat, Morocco

E-mail: benameur.yassir@gmail.com

liferative growth involving the upper one-third of anterior vaginal wall and the left parametrium was medially involved. Biopsy from the lesion was reported as squamous cell carcinoma of the cervix. Further imaging of the pelvis via MRI, ultrasound scan of the abdomen plus pelvis and X-ray postero-anterior view of the chest was performed. It showed a 38mmx47mmx42mm mass involving the cervix, with no evidence of hydronephrosis or infiltration into the surrounding organs such as the bladder or the rectum, or grossly enlarged pelvic or para-aortic nodes, and no distant metastasis into the lungs or the liver. No evaluation of any tumor marker was performed. The patient was diagnosed with International Federation of Gynecology and Obstetrics Stage IIIB cervical cancer (squamous cell carcinoma).

A whole body FDG-PET/CT scan was performed and revealed a large homogeneously enhancing soft tissue mass with increased FDG uptake involving the cervix (SUV_{max} : 6.8 (maximum standardized uptake value)). In addition to the primary tumor, the images demonstrated abnormal multifocal FDG uptake on several mediastinal and hilar lymph nodes stations: right paratracheal (SUV_{max} : 6.3); para-aortic (SUV_{max} : 8.7); Baretty space (SUV_{max} : 11.2); subaortic nodes (aortopulmonary window) (SUV_{max} : 10.9); subcarinal (SUV_{max} : 13.8) and bilateral hilar lymphadenopathy (SUV_{max} : 13.4) (Fig. 1). This uptake followed a lymphatic drainage pattern suggestive of a pulmonary neoplasm.

However, there was no evidence of an F18-FDG-avid pulmonary parenchymal lesion. Tissue sample swabs obtained by mediastinoscopy and subsequent biopsy of the subcarinal lymph node was consistent with a diagnosis of sarcoidosis.

Discussion

Sarcoidosis is a benign granulomatous disease of unknown etiology with pulmonary and extrapulmonary manifestations. This systemic inflammatory disease is characterized by the histopathologic appearance of noncaseating epithelioid cell granulomas.[1] Sarcoidosis has multiple clinical manifestations, ranging from single organ involvement (most frequently lungs, eyes, and skin), to a multisystem disease. The most commonly encountered pattern is mediastinal and hilar lymphadenopathy, with or without pulmonary parenchymal disease. Diagnosis is based on the presence of a compatible clinical-radiological pattern, together with histopathological evidence of granulomas.[2]

Sarcoidosis has been reported to occur in patients preceding, concurrent with, or after the diagnosis of cancer.[3] A causal relationship between sarcoidosis and the onset of several hematologic malignancies and solid tumors appears to exist; specifically, these include tumors that affect the liver, lung, skin, testicles, and cervix.[4] This association has been well described, but

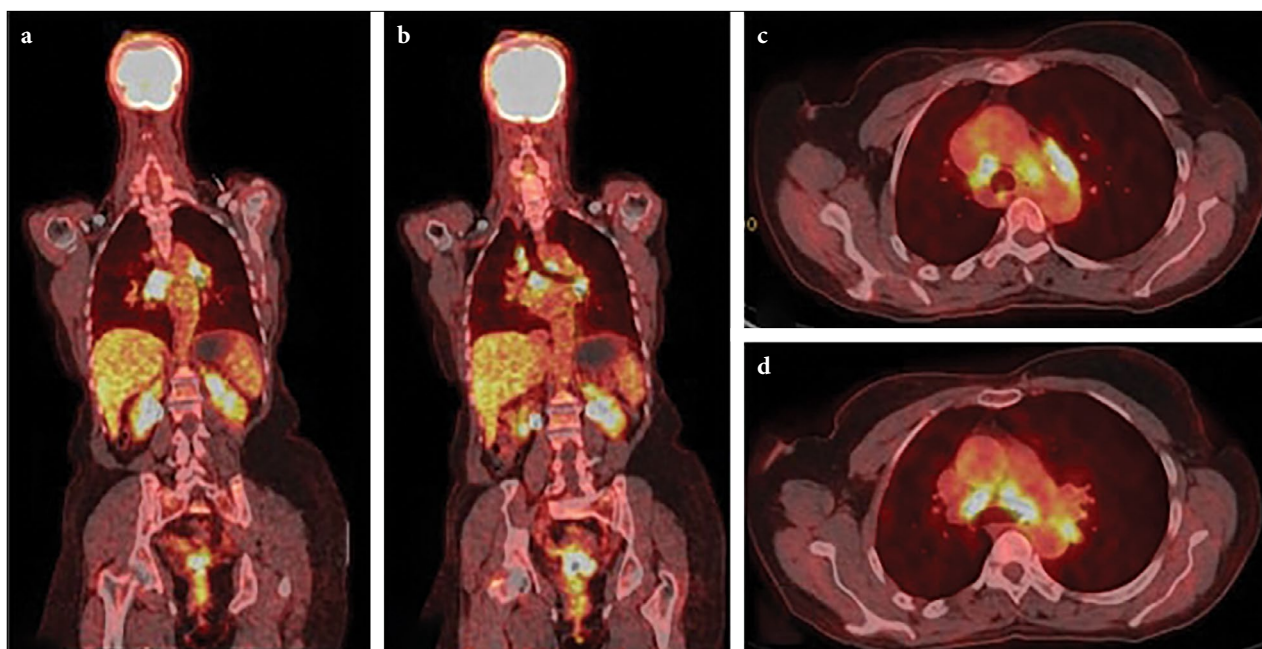


Fig. 1. Whole body FDG-PET/CT showing FDG uptake on mediastinal and hilar lymph nodes, on the coronal images (a,b); as well as on the transverse images (c,d).

the matter remains controversial: whether this association is just a coincidence or the consequence of a pathogenic mechanism, even if the last hypothesis is the most likely and the association might be non-fortuitous, as suggested by some reports which tried to connect cancer and sarcoidosis.[5] Several mechanisms have been proposed to explain the relationship between sarcoidosis and cancer. These include chronic inflammation, immune dysfunction, shared etiologic agents, and genetic susceptibility to both cancer and autoimmune diseases.[6] In addition, sarcoidosis might be a side effect of the chemotherapeutic treatments as it has been reported in hematologic malignancies. Especially alpha interferon, which is considerate, the most common postulated causative agent, although many other agents such as cisplatin, IL-2 for solid tumors have also been reported.[3] Therefore, a concentrated effort on prospective studies would be required to address this issue.

FDG-PET/CT has many proven applications beyond cancer imaging; its superior anatomic localization of increased metabolic activity has been found to be more sensitive for inflammatory or infectious processes such as sarcoidosis than other nuclear imaging techniques such as ⁶⁷Ga imaging.[7] Nevertheless; it has to be considered that PET/CT can lead to false-positive results in cases of infection and inflammation where glucose consumption is prevalent. Therefore, preoperative staging for a malignant tumor is sometimes difficult when swelling and intense FDG uptake in lymph nodes is observed.[8] Chundru et al.[9] proposed some criteria based on case reviews to distinguish sarcoidosis from malignancy on FDG-PET/CT: sarcoidosis typically demonstrates higher activity in the central mediastinal nodes than in the hilar and lobar nodes, affects both sides of the mediastinum symmetrically, not follows any specific lymph node drainage, and often does not present with a parenchymal lung lesion.

On our patient, the FDG-PET/CT scan revealed in addition to the known hypermetabolic tumor of the cervix FDG, avid mediastinal and hilar lymphadenopathies, with no other FDG uptake on the rest of the body, especially on pelvic lymph nodes. This “bypass” of lymphatic nodes of the abdomen and pelvis, and the absence of disseminated disease, drew our attention on a possible association of an inflammatory disease with the uterine tumor; mediastinoscopy was performed and histopathologic findings corroborate the diagnosis of sarcoidosis. Regardless of cancer prognosis and fortunately, the prognosis for sarcoidosis is favorable following glucocorticoid therapy, and the symptoms often resolve themselves spontaneously.[10]

Conclusion

In conclusion, sarcoidosis mimicking metastatic disease is a challenge in oncologic treatment decisions, and potentially underestimated in daily clinical routine. This case demonstrates that the clinical presentation and radiological examinations, including a FDG-PET/CT scan, may not be able to distinguish between metastatic lymph nodes and sarcoidosis lesions. It is important to consider that, in patients with cervix cancer in whom positive FDG-PET findings in the mediastinal lymph nodes were found; it should be speculated that these nodes may not be metastatic lymph nodes but may be granulomatous nodules. To prevent misdiagnosis and overtreatment, a tissue diagnosis is strongly recommended.

Informed consent: Written informed consent was obtained from the patient for the publication of the case report and the accompanying images.

Peer-review: Externally peer-reviewed.

Conflict of Interest: All authors declare that they have no conflict of interest.

Financial Disclosure: None declared.

Authorship contributions: Concept – Y.B., S.N.O., O.A.S., A.D.; Design – Y.B., A.D.; Supervision – A.D.; Data collection &/or processing – Y.B.; Analysis and/or interpretation – Y.B., A.D.; Literature search – Y.B.; Writing – Y.B., A.D.; Critical review – A.D.

References

1. Newman LS, Rose CS, Maier LA. Sarcoidosis. *N Engl J Med* 1997;336(17):1224–34.
2. Arish N, Kuint R, Sapir E, Levy L, Abutbul A, Fridlender Z, et al. Characteristics of Sarcoidosis in Patients with Previous Malignancy: Causality or Coincidence? *Respiration* 2017;93(4):247–52.
3. Shigemitsu H. Is sarcoidosis frequent in patients with cancer? *Curr Opin Pulm Med* 2008;14(5):478–80.
4. Cohen PR, Kurzrock R. Sarcoidosis and malignancy. *Clin Dermatol* 2007;25(3):326–33.
5. Alliot C, Barrios M, Desplechain C. Multisystem sarcoidosis and carcinoma of the uterine cervix: an unusual association. *Int J Gynecol Cancer* 2001;11(4):323–5.
6. Bonifazi M, Bravi F, Gasparini S, La Vecchia C, Gabrielli A, Wells AU, et al. Sarcoidosis and cancer risk: systematic review and meta-analysis of observational studies. *Chest* 2015;147(3):778–91.
7. Jolepalem P, McLean KZ, Wong CY. Atypical Present-

- tation of Sarcoidosis on ^{18}F -FDG PET/CT. *J Nucl Med Technol* 2014;42(2):114–5.
8. Takanami K, Kaneta T, Yamada T, Kinomura S, Yamada S, Fukuda H, et al. FDG PET for esophageal cancer complicated by sarcoidosis mimicking mediastinal and hilar lymph node metastases: two case reports. *Clin Nucl Med* 2008;33(4):258–61.
 9. Chundru S, Wong CY, Wu D, Balon H, Palka J, Chang CY, et al. Granulomatous disease: is it a nuisance or an asset during PET/computed tomography evaluation of lung cancers? *Nucl Med Commun* 2008;29(7):623–7.
 10. Goldstein BH, Rettenmaier MA, Sheffer EC, Chan K, Birk C, Brown JV 3rd, et al. Sarcoidosis imitating metastatic cervical cancer. *Arch Gynecol Obstet* 2008;277(5):441–3.