



Protective Role of Astaxanthin on Radiation-Related Intestinal Toxicity in Rats

Emine Elif ÖZKAN,¹ Özlem ÖZMEN,² İbrahim ÇOBANBAŞ,¹ İlter İLHAN³

¹Department of Radiation Oncology, Süleyman Demirel University, Isparta-Türkiye

²Department of Pathology, Mehmet Akif Ersoy University, Burdur-Türkiye

³Department of Biochemistry, Süleyman Demirel University, Isparta-Türkiye

OBJECTIVE

Radiation (RT)-induced intestinal toxicity is a common complication of abdominal or pelvic radiation therapy. Although the underlying pathological features are partially clarified, the appropriate treatment approach is not yet clear. Herein, we sought the protective role of astaxanthin (ATX), which is a natural antioxidant, on the RT-induced toxicity in the rat intestine.

METHODS

Male Wistar rats that are 10-12 weeks old and weighing 250-350 g were divided into four groups: control, RT alone, RT+ATX, and ATX alone as Groups 1, 2, 3, and 4, respectively. RT was given to the abdomen as one fraction of 8 Gy, and ATX was given as 4 mg/kg for 7 days before RT. Intestinal tissues were taken 24 h after the last ATX injection and radiation for histopathologic, immunohistochemical examination, and oxidative stress measurement.

RESULTS

Oxidative stress index and oxidant status decreased with ATX administration in the radiation group where an increase was reported in total antioxidant status. ATX treatment decreased the pathological expressions observed in the proprial and epithelial cells of the intestinal villi in the RT group. Similarly, RT exposure increased TNF- α expression while ATX treatment decreased the immunoreaction.

CONCLUSION

Our results demonstrate that radiation induces apoptosis and histopathologic intestinal mucosal changes which leads to an increase in oxidative stress. ATX significantly ameliorates radiation-induced reactions with its superior antioxidant properties and additional anti-inflammatory and antiapoptotic activities.

Keywords: Astaxanthin; oxidative stress; radiation-induced intestinal toxicity.

Copyright © 2022, Turkish Society for Radiation Oncology

INTRODUCTION

Radiation (RT) is an indisputable component of the tumor treatment algorithm taking into consideration that approximately 50% of these patients will need RT during their treatment.[1] Most of these patients

receive abdominal or pelvic radiation to treat pelvic malignancies or with palliative intent for pelvic bony metastasis, which leads to radiation-induced gastrointestinal injury. Therefore, finding out the mechanisms underlying this pathology may probably give way to developing effective treatments.[2]

Received: May 24, 2022

Accepted: June 01, 2022

Online: August 24, 2022

Accessible online at:

www.onkder.org

OPEN ACCESS This work is licensed under a Creative Commons Attribution-NonCommercial 4.0 International License.



Dr. Emine Elif ÖZKAN

Süleyman Demirel Üniversitesi,

Radyasyon Onkolojisi Anabilim Dalı,

Isparta-Türkiye

E-mail: ozkanelif@yahoo.com

Ionizing radiation (IR) can cause a prominent increment of intracellular reactive oxygen species (ROS), which causes a consequential intensive oxidative stress. Excess of these molecules causes irreversible damage to DNA, lipids, and proteins. They oxidize the cellular components with consequential tissue damages that lead to cell death via apoptosis.[3,4]

This justifies investigating efficient antioxidant molecules to prevent radiation-induced damage mediated by ROS and apoptosis. Therefore, various antioxidant compounds against radiation-induced oxidative stress became important targets of the investigation for radioprotective intend.[5,6] Radioprotective agents improve antioxidant status by decreasing free radicals, which consequently enhances DNA damage repair, and reduce radiation-induced inflammation.[5] A relatively new carotenoid astaxanthin (ATX), which is reported to relieve oxidant stress, has also been recently investigated.

ATX, a natural antioxidant that is a xanthophyll carotenoid of the carotenoid family member, is predominantly found in marine organisms or water plants such as fungi, microalgae, and other seafood.[7,8] It is reported to be the only carotenoid, which can pass the blood-brain barrier and get into the parenchyma by transcytosis to date.[7] Higher antioxidant activity than other similar carotenoid molecules (α - and β -carotene, lycopene, vitamin E, and lutein) is the other favored feature of ATX.[9] This higher antioxidant activity is attributed to the polar property of ATX, which provides a specific interaction with the cell membranes and protection of the membrane structure as a stronger antioxidant compared with the other nonpolar carotenoids.[10] Additional effective intracellular free radical scavenger role of ATX destroys peroxide chain reactions, which consequentially leads to impairment of its protective role for biological membranes and the cell itself from oxidative degradation.[11] The antioxidative and anti-inflammatory effects of ATX are shown in Figure 1.

Many studies reported hepatoprotective, antioxidative, anti-inflammatory, immunomodulatory, anti-diabetic, and antitumor activity of ATX, with no determined toxicity or side effects. Consequentially, it is widely used as a potential therapeutic agent in many indications.[7,12-14] The inhibiting role of ATX on carcinogenesis and antitumor effect in many cancer types such as oral cancer, colon cancer, leukemia, and hepatocellular carcinoma are also reported.[15-18]

Zhao and colleagues demonstrated the protective effect of ATX administration before irradiation on liver cells in terms of oxidative deterioration and DNA damage in irradiated mice.[19]

The antioxidant activity of other carotenoids has been investigated in reviews and meta-analyses; however, ATX has not been sufficiently searched yet.[20]

In this study, we investigated whether oral ATX administration could reduce the radiosensitivity of intestinal tissue via evaluating the changes in inflammatory markers [caspase 3, tumor necrosis factor-alpha (TNF- α), and biochemical markers of oxidative stress [total antioxidant status (TAS) and total oxidant status (TOS)]. We also sought radiation-induced histopathological and immunohistochemical changes in intestinal tissue.

MATERIALS AND METHODS

Animals

Wistar rats were provided from the Suleyman Demirel University Experimental Animal Laboratory. Animals were approximately 10-12 weeks old (250-350 g) and were taken care of under specific pathogen-free conditions where they had free access to nutrients and water. They were nursed in 42% relative humidity and a 12-h dark/light cycle at a stable temperature (20°C).

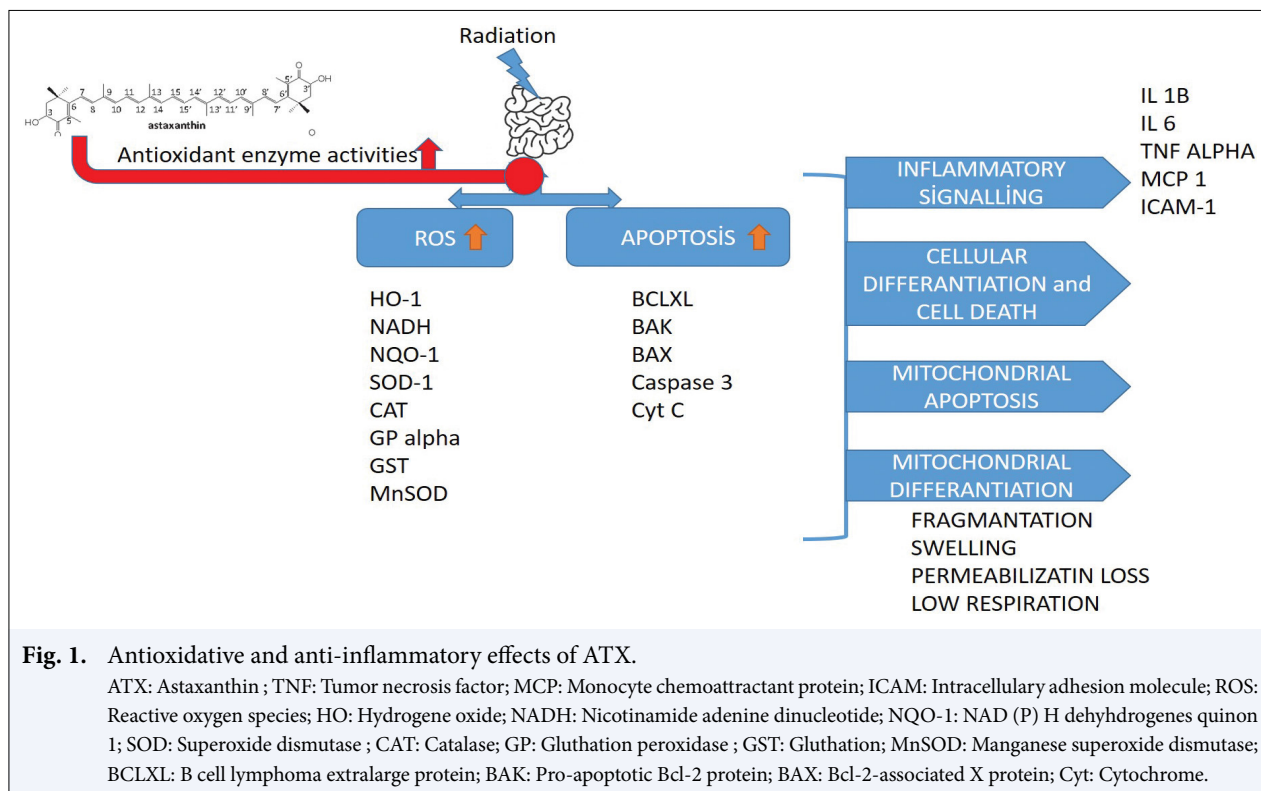
Rat food ingredients: raw oil 3%, ash 6.95%, lysine 1.3%, phosphorus 0.74%, protein 23.50%, cellulose 6.75%, methionine 0.43%, calcium 0.62%, and sodium 0.04%.

All procedures of the study were approved by the Animal Care and Ethics Committee of the Suleyman Demirel University (01-05/January 7, 2021). This study was supported by the Scientific Research Projects Coordination Unit of Suleyman Demirel University with project code TSG-2020-8134.

During the procedure, no weight loss of more than 15% was detected, which required stopping the experiment.

Groups of Animals

- I. Control group (n=8): This group was anesthetized with intraperitoneal 90 mg/kg ketamine and 10 mg/kg xylazine for sham radiation and had 1 mL saline solution with oral gavage for 7 days.
- II. RT group (n=8): This group underwent a single dose of 8 Gy X-ray abdominal radiation after being anesthetized and had 1 mL saline solution with oral gavage for 7 days.
- III. RT+ATX group (n=8): This group underwent radiation after being anesthetized and had 1 mL of 4 mg/kg ATX solution via oral gavage for 7 days.
- IV. ATX Group (n=8): This group was anesthetized for sham radiation and had 1 mL of 4 mg/kg ATX solution via oral gavage for 7 days.



ATX was used in a wide range of doses (2 µg/kg-100 mg/kg), which can be attributed to the difference in the searched effects in studies such as inhibiting proliferation, inducing apoptosis, and mitigation of radiation-induced hematopoietic system injury after TBI.[21,22] The study by Shao et al.[21] detected that proliferation inhibitory effect of ATX was dose-dependent and high-dose ATX had a higher inhibitory effect at 12 h and 24 h ($p < 0.05$).

Kim and Kim determined variable effects of ATX on oxidative stress with different doses in their review.[23] In our study, ATX was administered as 4 mg/kg, which was dissolved in 1% DMSO solution in line with previous studies.

Irradiation

Radiation was given using a Varian DHX linear accelerator with a fixed source to a surface distance of 98.5 cm and a single field size of 20 cm×21 cm, which covers the body of the rat. Anisotropic Analytical Algorithm dose calculation algorithm and 6 MV X-ray beam were used in the planning process, and 8 Gy with 600 MU/min was prescribed for irradiation. For investigating radiation-induced gastrointestinal adverse effects, 8.4, 9.4, and 10.4 Gy were administered in a study by Saha et al.[24] In our study, we used 8 Gy due to the higher dose rate of our system.

Treatment plans were created using the Eclipse treatment planning system. Beam's eye view is shown in Figure 2.

Incision and Tissue Evaluation

The surgical procedure was done 24 h after the last ATX administration under anesthesia. Following an abdominal incision, a part of the ileum was taken and stored at -20°C for biochemical analysis and embedded in a 10% solution of formaldehyde for histopathologic and immunohistochemical analysis.

Measurement of Oxidative Stress Parameters

Intestinal tissue samples were homogenized with Ultra Turrax Janke & Kunkel T-25 homogenizer (IKA®-Werke, Germany) for oxidant-antioxidant analysis. TAS and TOS were measured spectrophotometrically (Beckman Coulter AU 5800, Beckman Coulter, USA) using standard kits (Rel Assay Diagnostics, Gaziantep, Turkey). Oxidative stress index (OSI) was calculated using the formula: $OSI = TOS/TAS$. [25]

TAS analysis: Dark blue-green 2,2'-azino-bis(3-ethylbenzthiazoline-6-sulfonic acid) (ABTS) radical is reduced to colorless ABTS form via antioxidants in the sample.

The total level of antioxidants in the sample is evaluated according to the difference in absorbance at 660

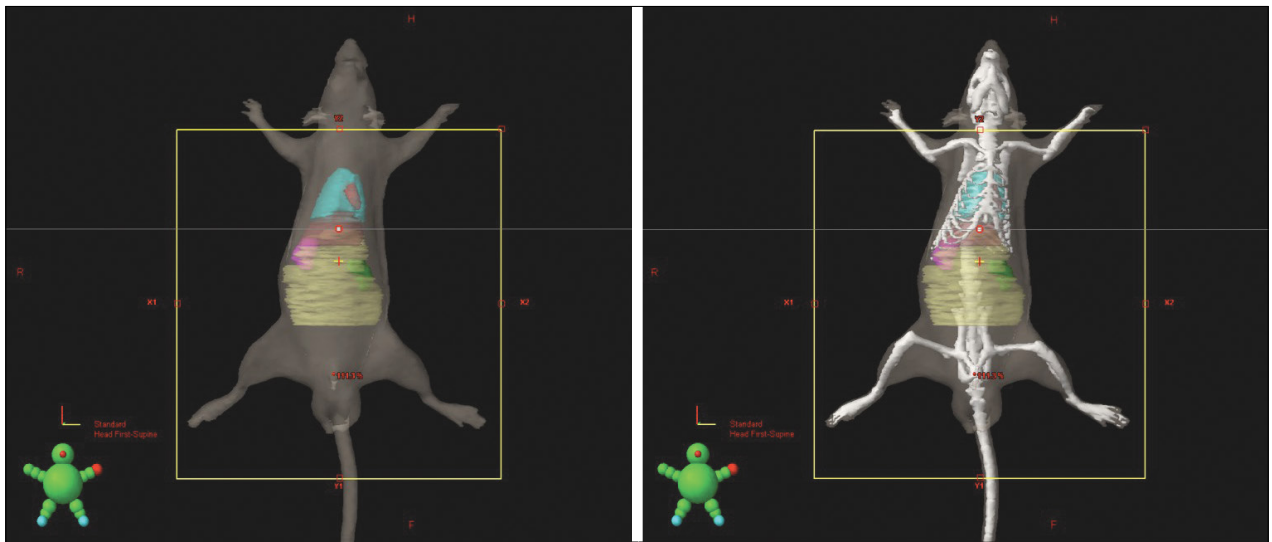


Fig. 2. Beam's eye view of rats on radiation treatment.

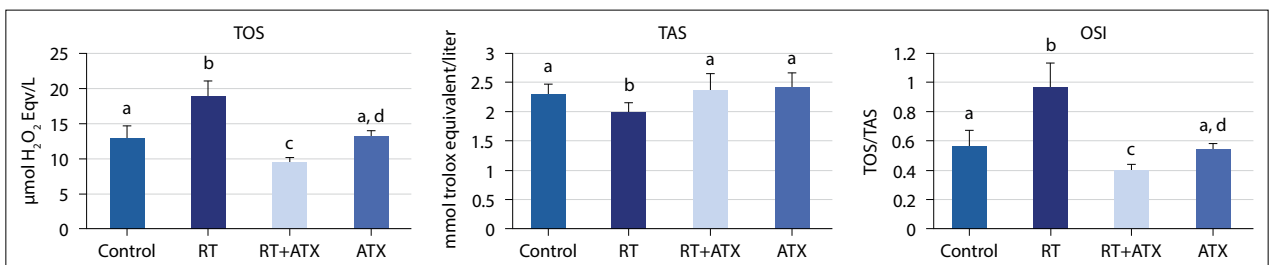


Fig. 3. Statistical analysis result of biochemical findings between the groups.

The differences between the means of groups carrying different letters between the groups are statistically significant, $p < 0.001$. Data are expressed as mean \pm standard deviation. One-way ANOVA LSD test was performed. TOS: Total oxidant status; TAS: Total antioxidant status; OSI: Oxidative stress index; RT: Radiation; ATX: Astaxanthin

nm. The determined antioxidative effect of the sample is expressed as millimolar Trolox equivalent per liter.[26]

TOS analysis: Ferrous ion-dianisidine complex turns into ferric ion via the oxidants in the sample. A colored complex is formed by the interaction of ferric ions with xylenol orange in an acidic medium. A spectrophotometric method is used to measure the color intensity, which relatively shows the total amount of oxidative species. Hydrogen peroxide was used for the calibration of the assay. The results were reported as micromolar hydrogen peroxide equivalent per liter ($\mu\text{mol H}_2\text{O}_2$ equiv./L).[27]

Histopathological Examination

Ileum samples were gently removed and fixed in a 10% solution of neutral formalin. After 24 h of fixation, tissue samples were trimmed and transferred to the tissue-processing cassette. Then, samples are processed with an automatic tissue processor (Leica ASP300S, Wetzlar, Germany) and embedded in paraffin wax. Sections of 5- μm

thickness were taken from the paraffin blocks by a rotary microtome (Leica RM2155, Leica Microsystems, Wetzlar, Germany). The sections were stained with hematoxylin-eosin coverslip and examined under a light microscope. In the morphometric analysis of the intestines, the height and width of the villus were measured in each rat.

Immunohistochemical Examination

For immunohistochemical examination, two series of sections taken from all blocks of the intestine drawn on poly-L-lysine coated slides were stained immunohistochemically for caspase-3 [anti-caspase-3 antibody (E-8): sc-7272] and TNF- α (anti-TNF α antibody (52B83): sc-52746, 1/100 dilution] Santa Cruz (Texas, USA) expression according to the manufacturer's instruction. The sections were incubated with primary antibodies for 60 min, and immunohistochemical analysis was done by a conjugate of a biotinylated secondary antibody and streptavidin-alkaline phosphatase. EXPOSE

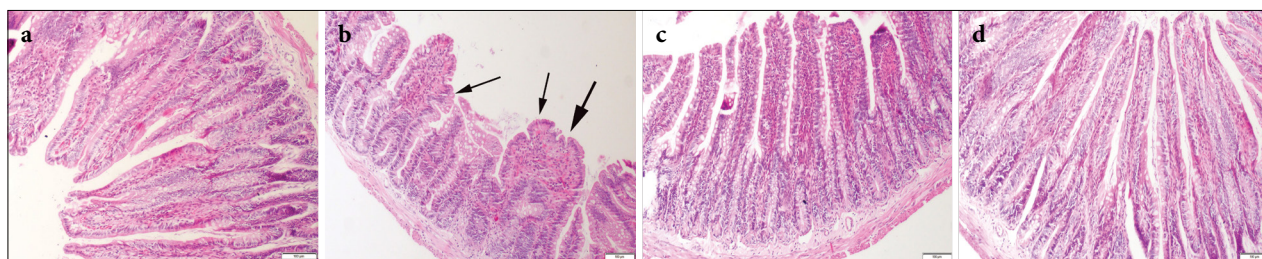


Fig. 4. Histopathological appearance of the gut samples between the groups. (a) Normal tissue histology in the control group; (b) marked shortage, fusion (thick arrow), and irregular proliferation (arrows) in the villi; (c) decreased pathological findings in the RT+ATX group; (d) normal intestinal architecture in the ATX group. HE, scale bars=100 µm. RT: Radiation; ATX: Astaxanthin; HE: hematoxylin and eosin.

Mouse and Rabbit Specific HRP/DAB Detection IHC kit (ab80436) (Abcam, Cambridge, UK) was used as the secondary antibody. Diaminobenzidine (DAB) was used as the chromogen. For negative controls, instead of a primary antibody, antigen dilution solution was used. A specialized pathologist from another university performed all processes on blinded samples.

For immunohistochemical analysis, sections were separately investigated for each antibody. To evaluate the severity of the immunohistochemical reaction of cells with markers, semiquantitative analysis was performed using a grading score ranging from 0 to 3 as follows: 0=negative, 1=weak and focal, 2=weak and diffuse, and 3=strong and diffuse. For evaluation, 10 different areas under 40× objective magnification in each section were examined. Morphometric analyses and microphotography were performed via Database Manual Cell Sens Life Science Imaging Software System (Olympus Co., Tokyo, Japan). The results were saved and statistically analyzed.

Statistical Analysis

For statistical analysis, the immunohistochemical scores of the groups were compared using the one-way ANOVA Duncan test (SPSS-22.00 package program). The level of significance was considered at $p < 0.05$.

RESULTS

ATX Decreased Oxidative Stress Markers

TOS levels increased in the RT group compared with the control group ($p < 0.001$), and it was decreased in both ATX administrated (RT+ATX and ATX) groups compared with the RT group ($p < 0.001$ for both). TOS levels were decreased in the RT + ATX group compared with the ATX group ($p < 0.001$). TAS levels were lower than the control group in the RT group ($p = 0.028$) and increased in both ATX administrated groups in comparison with the RT group ($p = 0.007$ for both). OSI lev-

els increased in the RT group according to the control group ($p < 0.011$) and in the RT+ATX group, OSI levels decreased compared with the ATX group ($p < 0.02$). Statistical analysis is plotted in Figure 3.

ATX Decreased Histopathological Findings Induced by Radiation

In the histopathological analyses of the intestinal samples, no histological abnormalities were reported in the control group. Histological analysis showed that radiation caused crypt damage and inflammatory reaction at the mucosal layer. Shortened and fused villi were noticed in the intestinal mucosa in addition to irregular proliferation. Inflammatory cell infiltrations at the propria mucosa were the other marked finding in the RT group. ATX treatment decreased the pathological findings in the RT+ATX group. Normal tissue histology was seen in the ATX group (Fig. 4). Statistical plots of the height and width of villi are shown in Table 1. Statistical analysis is also plotted in Figure 5.

ATX Decreased TNF- α and Caspase-3 Expression

At the immunohistochemical analysis, increased expressions were observed in proprial and epithelial cells of the intestinal villi in the RT group while very slight to no expression in the control group. Decreased caspase-3 expressions were observed in the RT+ATX group ($p < 0.001$). No or slight expressions were noticed in the ATX group (Fig. 6). Similarly, RT exposure increased TNF- α expression while ATX treatment decreased the immunoreaction ($p < 0.01$) (Fig. 7). Statistical evaluation of immunohistochemical scores is plotted in Table 1.

DISCUSSION

Radiation therapy is an increasingly used modality in multimodal cancer treatment strategy, especially in the treatment of gynecological and colorectal cancer.

Table 1 Statistical analysis result of height and width of villi and immunohistochemical scores between the groups

Groups	Width (µm)	Height (µm)	Inflammation	Goblet cell number	Caspase-3 score	TNF-α score
Control	22.14±5.66 ^{ab}	1023.71±36.14 ^a	0.00±0.00 ^a	24.14±1.77 ^{ab}	0.14±0.14 ^a	0.14±0.14 ^a
RT	45.71±6.72 ^c	692.85±48.29 ^b	1.28±0.75 ^b	12.57±1.71 ^c	2.14±0.69 ^b	1.42±0.53 ^b
RT+ATX	27.85±7.55 ^b	899.28±74.41 ^c	0.14±0.14 ^a	23.42±2.29 ^b	0.42±0.20 ^a	0.57±0.53 ^a
ATX	18.57±5.56 ^a	1039.28±47.11 ^a	0.00±0.00 ^a	25.71±1.11 ^a	0.14±0.14 ^a	0.14±0.14 ^a
p	<0.001	<0.001	<0.001	<0.001	<0.001	<0.001

The differences between the means of groups carrying different letters between the groups are statistically significant, p<0.001. Data are expressed as mean±standard deviation. One-way ANOVA Duncan test was performed. TNF-α: Tumor necrosis factor-alpha; RT: Radiation; ATX: Astaxanthin

About 60% of patients with gynecological or colorectal cancer have received radiation therapy, and about 75% of them have radiation-related gastrointestinal symptoms emerging as diarrhea, abdominal pain, malabsorption, rectal bleeding, urgency, and fecal incontinence with varying severity.[28-30]

This remarkable sensitivity of the intestine is attributed to the retainable intensive proliferative activity of the epithelial cell compartment.

Radiation-induced gastrointestinal toxicity is mainly a result of massive apoptosis in crypt epithelial cells and villus stromal cells, which leads to a consequential mucosal barrier dispersal followed by intestinal bleeding, electrolyte imbalance, and even sepsis.[24,31-33] The resultant immune suppression due to enterocyte depletion and intestinal ablation is the manifestation of gastrointestinal acute radiation toxicity syndrome.

[24,31-34] Recovery of the intestinal epithelium is provided by the regeneration of stem cells in the intestinal crypts.[35,36] Increased survival of the progenitor cells, mobilization, and proliferation of survived stem cells are the two main factors for regeneration of the GI system.[37] Modulation of regeneration responses and vulnerability to cytotoxic injury are possible with a better understanding of the endogenous mechanisms, which sustain mucosal integrity.[38]

IR causes free radical excess through the lysis of water molecules and causes cell death by DNA damage after interacting with tissues. Intracellular antioxidant expression increases to reduce the cellular damage due to free radicals formed after IR exposure. Therefore, natural products with potential antioxidant and immune-stimulant activity became the subject of recent investigations as effective radioprotectors.[39]

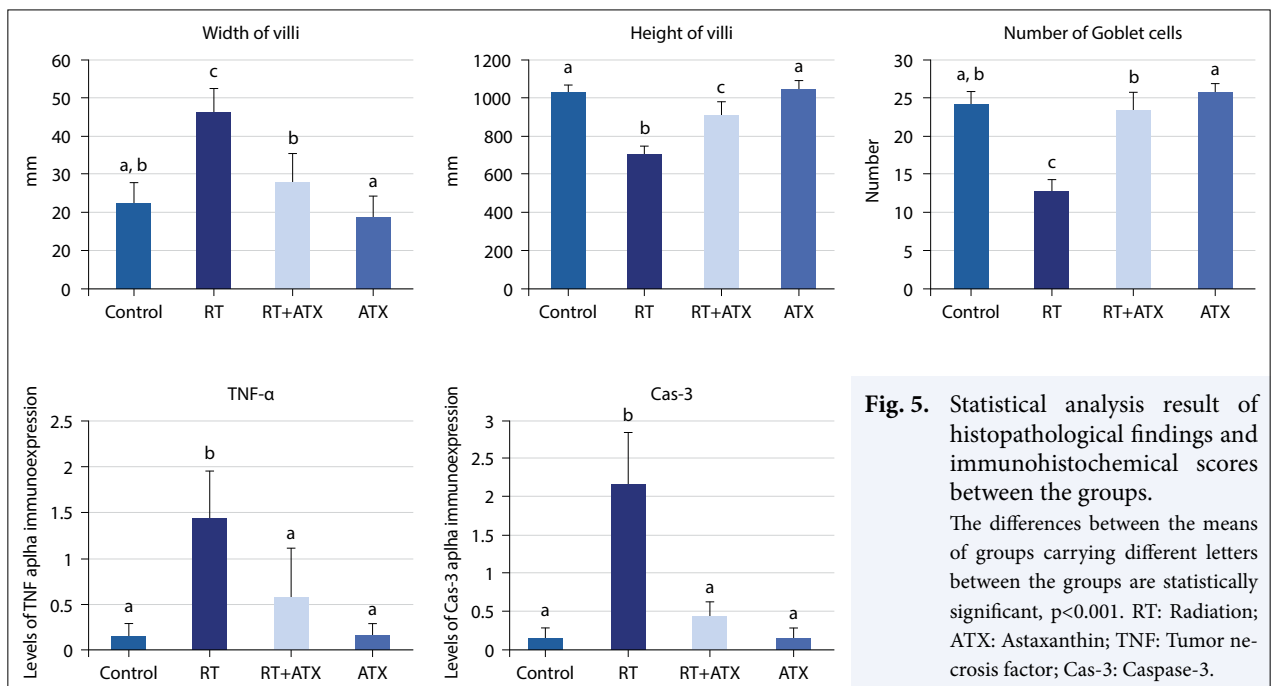


Fig. 5. Statistical analysis result of histopathological findings and immunohistochemical scores between the groups. The differences between the means of groups carrying different letters between the groups are statistically significant, p<0.001. RT: Radiation; ATX: Astaxanthin; TNF: Tumor necrosis factor; Cas-3: Caspase-3.

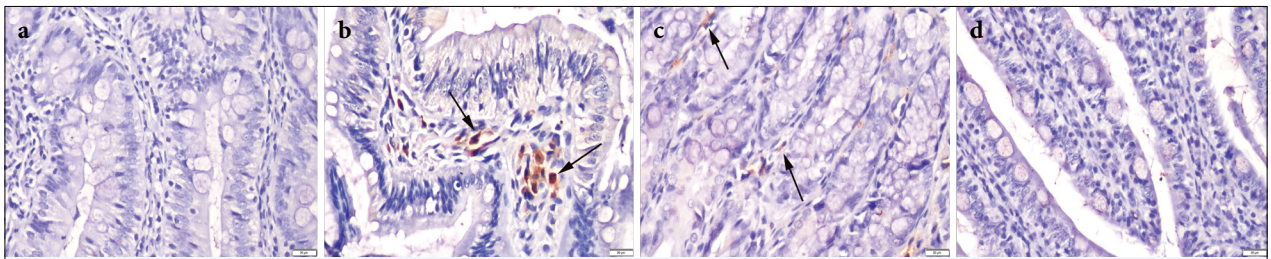


Fig. 6. Caspase-3 immunohistochemistry findings between the groups. (a) Negative expression in the control group; (b) increased expressions in proprial cells (arrows) in RT group; (c) decreased expressions (arrows) in RT+ATX group; (d) no expression in the ATX group (streptavidin-biotin peroxidase method, scale bars=20 µm.

RT: Radiation; ATX: Astaxanthin.

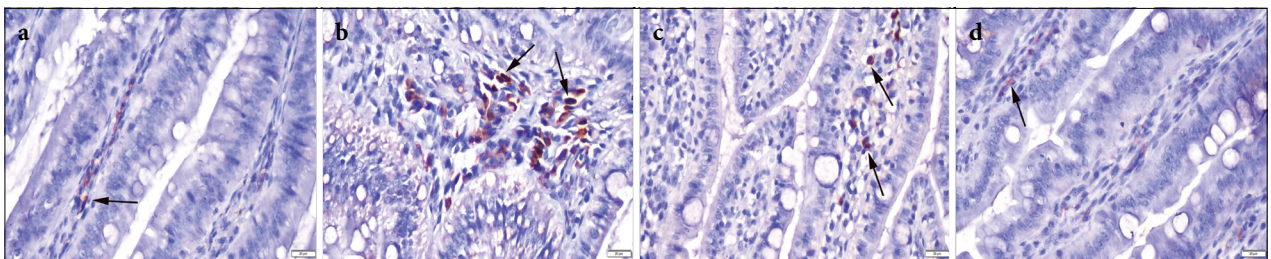


Fig. 7. TNF-α immunohistochemistry findings among the groups. (a) Very slight expression (arrow) in the control group; (b) increased expressions in proprial cells (arrows) in the RT group; (c) decreased immunoreaction (arrows) in the RT+ATX group; (d) very slight expression (arrow) in the ATX group (streptavidin-biotin peroxidase method, scale bars=20 µm.

Data expressed mean±standard deviation. One-way ANOVA Duncan test was performed.

ATX is approved as a food colorant[40] and is also used as a supplementary healthcare product because of its superior antioxidant activity.[41] However, the evidence on the potential effect of ATX as a radioprotector is still scarce.[22] Kurinnyi et al.[42] determined that ATX stimulates apoptosis in the cells after RT and a consequential decrease in DNA damage and it also scavenges ROS, which reduces DNA breaks.

Many previous studies proved the anticancer effect of ATX via decreasing mRNA and protein levels of MMP-2 and MMP-9, inducing apoptosis and regulating the expressions of NF-κB, and inhibiting invasion and angiogenesis through downregulation of JAK-2/STAT-3 leading to inhibition of tumor development and progression.[15,16,18,43] Interpretation of these results assures the fact that the protective effect of ATX is only on surrounding normal tissues not in the malignant tissue.

In our study, we assessed TAS, TOS, OSI, histopathological changes, and immunohistochemical marker variations in the intestinal tissues to detect the radioprotective effect of ATX on intestinal injury after abdominal pelvic irradiation.

Oxidative stress is known to be one of the major mediators of radiation damage, and protection of re-

dox balance facilitates tissue recovery [33]. In a meta-analysis by Wu et al.,[44] ATX is suggested as an effective reducer of oxidative stress, and it is also shown that ATX enhances plasma antioxidant capability. In our study, we have detected an increase in TOS levels with radiation, which was decreased with the addition of ATX. OSI levels were also increased with RT and decreased via ATX administration. We attributed the decreased levels of TOS and OSI in RT-ATX group compared with both RT-only and ATX-only groups, to the mitigation of oxidative stress due to an increase in antioxidative enzymes and anti-inflammatory effect. The increase in antioxidative enzymes and anti-inflammatory effect results in a double reducing effect on oxidative stress, which increases the effect of ATX when administered with radiation. These results were in line with recent similar reports.[44]

In a study with 50 mice in five groups, the protective effect of *Haematococcus pluvialis* (containing ATX) against any antioxidative system damage and DNA damage induced by Co60 gamma-rays. In line with our results, superoxide dismutase and other oxidative stress products were higher in the model group than in the control group. Compared with the control group, the

same contents were decreased ($p < 0.01$) in all Haematoctococcus pluvialis groups. Conclusively, ATX was suggested as a protector against oxidative deterioration and DNA damage in mice induced by gamma-rays.[19]

Shortened and fused villi, irregular proliferation in intestinal mucosa, and inflammatory cell infiltrations at the propria mucosa were the histological changes revealing radiation-caused crypt damage and inflammatory reaction at the mucosal layer induced by radiation. The addition of ATX to the RT group decreased the pathological findings caused by RT.

Goblet cells are a quantitatively important population of the small intestine epithelium.[45] Mucus secreted by the goblet cells constitutes a protective barrier and functions as a lubricant for the digestive tract.[46] However, results about the reaction of goblet cells during radiation injury are conflicting. There are several published reports[45,46] suggesting an increase in the number of goblet cells postradiation whereas a few studies detected a lower number of goblet cells during radiation injury. However, on the other hand, there are also few reports.[47] In our study, we showed the number of goblet cells significantly increased in ATX+RT groups.

Immunohistochemical expression was increased in proprial and epithelial cells of intestinal villi in the RT group. However, in the RT+ATX group, expressions were decreased. No or slight expressions were noticed in the ATX-only group (Fig. 3).

TNF- α is a major regulator for the activation of pro-inflammatory cytokines and mediates phosphorylation of kinases, which induces transcription of inflammatory mediators.[48] ATX is shown to alleviate TNF- α -induced extracellular matrix degradation and apoptosis.[49] In their study, Kumar et al.[50] observed a significant decrease in serum TNF- α levels with 5 mg/kg ATX administration.

Similar to the above-mentioned studies, we observed an increased TNF- α expression with RT exposure, but immunoreaction in the intestinal tissue is decreased with ATX.

Giris et al.[51] reported significantly higher caspase activity in the intestinal and pancreatic tissue of the irradiated animal group ($p < 0.001$). The authors demonstrated that apoptosis or oxidative stress-related tissue damage is an important part of the mechanisms underlying consequences of abdominopelvic radiation and is also assessed by increased caspase-3 levels. The results of this study have also shown that caspases are also effective in apoptotic signal transduction. ATX decreases apoptosis significantly by itself and via decreasing caspase-3 levels.[52] In a study with oral ATX in

diabetic mice, ATX was found to decrease the amount of cleaved caspase-3-positive cells in the functional regions of mice. The authors concluded that oral ATX administration for 10 weeks caused a significant reduction of caspase-3 levels in diabetic mice and reduced the neuron damage in the hypothalamus.[53]

Limitations of the Study

An important limitation of our study is that no data in terms of ROS such as SOD, catalase, and glutathione in the intestinal pathological tissue section were given. Another issue to be mentioned is the absence of gene expression analysis for other inflammatory cytokines such as IL-6, IL-1 β , and TNF- α .

CONCLUSION

Our results demonstrate that radiation induces apoptosis, histopathologic intestinal mucosal changes, and immunohistochemical changes. ATX significantly ameliorates radiation-induced reactions with its superior antioxidant properties and additional anti-inflammatory and antiapoptotic activities. These findings encourage new randomized controlled phase III studies investigating the protective role of ATX in terms of acute intestinal radiotoxicity on patients receiving abdominal or pelvic radiation suggesting ATX as a new radioprotective agent.

Peer-review: Externally peer-reviewed.

Conflict of Interest: All authors declared no conflict of interest.

Ethics Committee Approval: The study was approved by the Animal Care and Ethics Committee of the Suleyman Demirel University (no: 01-05, date: 07/01/2021).

Financial Support: None declared.

Authorship contributions: Concept – E.E.Ö.; Design – Ö.Ö.; Supervision – E.E.Ö.; Funding – None; Materials – İ.İ.; Data collection and/or processing – E.E.Ö.; Data analysis and/or interpretation – E.E.Ö.; Literature search – İ.Ç.; Writing – E.E.Ö.; Critical review – İ.Ç.

REFERENCES

1. Delaney G, Jacob S, Featherstone C, Barton M. The role of radiotherapy in cancer treatment: estimating optimal utilization from a review of evidence-based clinical guidelines. *Cancer* 2005;104(6):1129–37.
2. Andreyev HJ. Gastrointestinal problems after pelvic

- radiotherapy: the past, the present, and the future. *Clin Oncol (R Coll Radiol)* 2007;19(10):790–9.
3. Hayashi T, Hayashi I, Shinohara T, Morishita Y, Nagamura H, Kusunoki Y, et al. Radiation-induced apoptosis of stem/progenitor cells in human umbilical cord blood is associated with alterations in reactive oxygen and intracellular pH. *Mutat Res* 2004;556(1–2):83–91.
 4. Xiao M, Whitnall MH. Pharmacological countermeasures for the acute radiation syndrome. *Curr Mol Pharmacol* 2009;2(1):122–33.
 5. Smith TA, Kirkpatrick DR, Smith S, Smith TK, Pearson T, Kailasam A, et al. Radioprotective agents to prevent cellular damage due to ionizing radiation. *J Transl Med* 2017;15(1):232.
 6. Prasanna PG, Stone HB, Wong RS, Capala J, Bernhard EJ, Vikram B, et al. Normal tissue protection for improving radiotherapy: Where are the Gaps? *Transl Cancer Res* 2012;1(1):35–48.
 7. Yuan J P, Peng J, Yin K, Wang J H. Potential health-promoting effects of astaxanthin: a high-value carotenoid mostly from microalgae. *Mol Nutr Food Res* 2011;55(1):150–65.
 8. Fassett RG, Coombes JS. Astaxanthin in cardiovascular health and disease. *Molecules* 2012;17(2):2030–48.
 9. Radzali SA, Baharin BS, Othman R, Markom M, Rahman RA. Co-solvent selection for supercritical fluid extraction of astaxanthin and other carotenoids from *Penaeus monodon* waste. *J Oleo Sci* 2014;63(8):769–77.
 10. McNulty H, Jacob RF, Mason RP. Biologic activity of carotenoids related to distinct membrane physicochemical interactions. *Am J Cardiol* 2008;101(10A):20–9.
 11. Li W, Hellsten A, Jacobsson LS, Blomqvist HM, Olsson AG, Yuan XM. Alphatocopherol and astaxanthin decrease macrophage infiltration, apoptosis and vulnerability in atherosclerosis of hyperlipidaemic rabbits. *J Mol Cell Cardiol* 2004;37:969–78.
 12. Ikeuchi M, Koyama T, Takahashi J, Yazawa K. Effects of astaxanthin in obese mice fed a high-fat diet. *Biosci Biotechnol Biochem* 2007;71:893–99.
 13. Pashkow FJ, Watumull DG, Campbell CL. Astaxanthin: a novel potential treatment for oxidative stress and inflammation in cardiovascular disease. *Am J Cardiol* 2008;101:58–68.
 14. Zhang L, Wang H. Multiple mechanisms of anticancer effects exerted by astaxanthin. *Mar Drugs* 2015;13(7):4310–30.
 15. Kavitha K, Kowshik J, Kishore TK, Baba AB, Nagini S. Astaxanthin inhibits NF- κ B and Wnt/ β -catenin signaling pathways via inactivation of Erk/MAPK and PI3K/Akt to induce intrinsic apoptosis in a hamster model of oral cancer. *Biochim Biophys Acta* 2013;1830(10):4433–44.
 16. Nagendraprabhu P, Sudhandiran G. Astaxanthin inhibits tumor invasion by decreasing extracellular matrix production and induces apoptosis in experimental rat colon carcinogenesis by modulating the expressions of ERK-2, NF κ B and COX-2. *Invest New Drugs* 2011;29(2):207–24.
 17. Zhang X, Zhao WE, Hu L, Zhao L, Huang J. Carotenoids inhibit proliferation and regulate expression of peroxisome proliferators-activated receptor gamma (PPAR γ) in K562 cancer cells. *Arch Biochem Biophys* 2011;512(1):96–106.
 18. Song X, Wang M, Zhang L, Zhang J, Wang X, Liu W, et al. Changes in cell ultrastructure and inhibition of JAK1/STAT3 signaling pathway in CBRH-7919 cells with astaxanthin. *Toxicol Mech Methods* 2012;22(9):679–86.
 19. Zhao W, Jing X, Chen C, Cui J, Yang M, Zhang Z. Protective effects of astaxanthin against oxidative damage induced by ⁶⁰Co gamma-ray irradiation. *J Hyg Res* 2011;40(5):551–54.
 20. Chen J, Song Y, Zhang L. Effect of lycopene supplementation on oxidative stress: an exploratory systematic review and meta-analysis of randomized controlled trials. *J Med Food* 2013;16(5):361–74.
 21. Shao Y, Ni Y, Yang J, Lin X, Li J, Zhang L. Astaxanthin inhibits proliferation and induces apoptosis and cell cycle arrest of mice H22 hepatoma cells. *Med Sci Monit* 2016;22:2152–60.
 22. Xue XL, Han XD, Li Y, Chu XF, Miao WM, Zhang JL, et al. Astaxanthin attenuates total body irradiation-induced hematopoietic system injury in mice via inhibition of oxidative stress and apoptosis. *Stem Cell Res Ther* 2017;8(1):7.
 23. Kim SH, Kim H. Inhibitory effect of astaxanthin on oxidative stress-induced mitochondrial dysfunction—a mini-review. *Nutrients* 2018;10(9):1137.
 24. Saha S, Bhanja P, Liu L, Alfieri AA, Yu D, Kandimalla ER, et al. TLR9 agonist protects mice from radiation-induced gastrointestinal syndrome. *PLoS One* 2012;7(1):e29357.
 25. Altindag O, Erel O, Soran N, Celik H, Selek S. Total oxidative/anti-oxidative status and relation to bone mineral density in osteoporosis. *Rheumatol Int* 2008;28(4):317–21.
 26. Erel O. A novel automated direct measurement method for total antioxidant capacity using a new generation, more stable ABTS radical cation. *Clin Biochem* 2004;37(4):277–85.
 27. Erel O. A new automated colorimetric method for measuring total oxidant status. *Clin Biochem* 2005;38(12):1103–11.
 28. Abayomi J, Kirwan J, Hackett A, Bagnall G. A study to investigate women's experiences of radiation enteritis following radiotherapy for cervical cancer. *J Hum*

- Nutr Diet 2005;18(5):353–63.
29. Hauer-Jensen M, Denham JW, Andreyev HJ. Radiation enteropathy--pathogenesis, treatment and prevention. *Nat Rev Gastroenterol Hepatol* 2014;11(8):470–9.
 30. Hauer-Jensen M, Wang J, Denham JW. Bowel injury: current and evolving management strategies. *Semin Radiat Oncol* 2003;13(3):357–71.
 31. Singh VK, Newman VL, Berg AN, MacVittie TJ. Animal models for acute radiation syndrome drug discovery. *Expert Opin Drug Discov* 2015;10(5):497–517.
 32. Withers HR, Elkind MM. Dose-survival characteristics of epithelial cells of mouse intestinal mucosa. *Radiology* 1968;91(5):998–1000.
 33. Hall EJ, Giaccia AJ. *Radiobiology for the radiobiologist*. 6th ed. Philadelphia: Lippincott Williams and Wilkins; 2006.
 34. Chen H, Min XH, Wang QY, Leung FW, Shi L, Zhou Y, et al. Pre-activation of mesenchymal stem cells with TNF- α , IL-1 β and nitric oxide enhances its paracrine effects on radiation-induced intestinal injury. *Sci Rep* 2015;5:8718.
 35. Booth D, Potten CS. Protection against mucosal injury by growth factors and cytokines. *J Natl Cancer Inst Monogr* 2001;(29):16–20.
 36. Gong W, Guo M, Han Z, Wang Y, Yang P, Xu C, et al. Mesenchymal stem cells stimulate intestinal stem cells to repair radiation-induced intestinal injury. *Cell Death Dis* 2016;7(9):e2387.
 37. Venkateswaran K, Shrivastava A, Agrawala PK, Prasad AK, Devi SC, Manda K, et al. Mitigation of radiation-induced gastro-intestinal injury by the polyphenolic acetate 7, 8-diacetoxy-4-methylthiocoumarin in mice. *Sci Rep* 2019;9(1):14134.
 38. Beck PL, Wong JF, Li Y, Swaminathan S, Xavier RJ, Devaney KL, et al. Chemotherapy- and radiotherapy-induced intestinal damage is regulated by intestinal trefoil factor. *Gastroenterology* 2004;126(3):796–808.
 39. Demir E, Taysi S, Ulusal H, Kaplan DS, Cinar K, Tarakcioglu M. *Nigella sativa* oil and thymoquinone reduce oxidative stress in the brain tissue of rats exposed to total head irradiation. *Int J Radiat Biol* 2020;96(2):228–35.
 40. Lorenz RT, Cysewski GR. Commercial potential for *Haematococcus microalgae* as a natural source of astaxanthin. *Trends Biotechnol* 2000;18:160–67.
 41. Wang M, Zhang J, Song X, Liu W, Zhang L, Wang X, et al. Astaxanthin ameliorates lung fibrosis *in vivo* and *in vitro* by preventing transdifferentiation, inhibiting proliferation, and promoting apoptosis of activated cells. *Food Chem Toxicol* 2013;56:450–58.
 42. Kurinnyi DA, Rushkovsky SR, Demchenko OM, Pilinska MA. Peculiarities of modification by astaxanthin of radiation-induced damages in the genome of human blood lymphocytes exposed *in vitro* on different stages of the mitotic cycle. *Cytol Genet* 2018;52:40–5.
 43. Kowshik J, Baba AB, Giri H, Deepak Reddy G, Dixit M, Nagini S. Astaxanthin inhibits JAK/STAT-3 signaling to abrogate cell proliferation, invasion and angiogenesis in a hamster model of oral cancer. *PLoS One* 2014;9(10):e109114.
 44. Wu D, Xu H, Chen J, Zhang L. Effects of astaxanthin supplementation on oxidative stress. *Int J Vitam Nutr Res* 2020;90(1–2):179–94.
 45. Becciolini A, Balzi M, Fabbrica D, Potten CS. The effects of irradiation at different times of the day on rat intestinal goblet cells. *Cell Prolif* 1997;30(3–4):161–70.
 46. Akpolat M, Kanter M, Uzal MC. Protective effects of curcumin against gamma radiation-induced ileal mucosal damage. *Arch Toxicol* 2009;83(6):609–17.
 47. Ettarh RR, Hodges GM, Carr KE. Radiation effects in the small bowel of the diabetic mouse. *Int J Radiat Biol* 2000;76(2):241–8.
 48. Brzustewicz E, Bryl E. The role of cytokines in the pathogenesis of rheumatoid arthritis—Practical and potential application of cytokines as biomarkers and targets of personalized therapy. *Cytokine* 2015;76:527–36.
 49. Sun K, Luo J, Jing X, Guo J, Yao X, Hao X, et al. Astaxanthin protects against osteoarthritis via Nrf2: a guardian of cartilage homeostasis. *Aging (Albany NY)* 2019;11(22):10513–31.
 50. Kumar A, Dhaliwal N, Dhaliwal J, Dharavath RN, Chopra K. Astaxanthin attenuates oxidative stress and inflammatory responses in complete Freund-adjvant-induced arthritis in rats. *Pharmacol Rep* 2020;72(1):104–14.
 51. Giriş M, Erbil Y, Oztezcan S, Olgaç V, Barbaros U, Deveci U, et al. The effect of heme oxygenase-1 induction by glutamine on radiation-induced intestinal damage: the effect of heme oxygenase-1 on radiation enteritis. *Am J Surg* 2006;191(4):503–9.
 52. Yiğit M, Güneş A, Uğuz C, Yalçın TÖ, Tök L, Öz A, et al. Effects of astaxanthin on antioxidant parameters in ARPE-19 cells on oxidative stress model. *Int J Ophthalmol* 2019;12(6):930–5.
 53. Zhou XY, Zhang F, Hu XT, Chen J, Tang RX, Zheng KY, et al. Depression can be prevented by astaxanthin through inhibition of hippocampal inflammation in diabetic mice. *Brain Res* 2017;1657:262–8.